ARTICLE IN PRESS
+ MODEL
Journal of Plastic, Reconstructive & Aesthetic Surgery (2011) xx, 1–6

ELSEVIER

JPRAS
An International Journal of Surgical Reconstruction
www.JPRASurg.com

Total lower-eyelid reconstruction: Modified Fricke's cheek flap

Julio Barba-Gómez [a], Omar Zuñiga-Mendoza [a], Itzel Iñiguez-Briseño [a], María Trinidad Sánchez-Tadeo [a], José Fernando Barba-Gómez [a], Nelly Molina-Frechero [b], Ronell Bologna-Molina [c,*]

[a] *Department of Surgery, Instituto Dermatológico de Jalisco 'Dr. José Barba Rubio' Secretaria de Salud Jalisco, Guadalajara, Mexico*
[b] *Health Care Department, Universidad Autónoma Metropolitana-Xochimilco, Mexico City, Mexico*
[c] *School of Dentistry, Research Department, Juarez University of Durango State, Durango, Mexico*

Received 24 March 2011; accepted 28 June 2011

KEYWORDS
Modified Fricke's cheek flap;
Lower eyelid;
Reconstruction

Summary The present work reviews a total lower-eyelid reconstruction technique that is currently not widely in use but which, in some cases, has proven to be of great utility in the field of reconstructive plastic surgery of the palpebral area.

We performed an observational, longitudinal, descriptive and retrospective follow-up study. A total of 34 cases of non-melanoma skin cancer in which the lower eyelid was completely reconstructed using one flap taken from the cheek (modified Fricke's cheek flap) were reviewed. The follow-up time for the patients ranged from several months to 5 years. Analysis was performed using the Pearson's chi-square statistical test in an effort to examine the association between the technique's range of functionality and aesthetic variables. Results were considered significant with a $p < 0.05$.

The functional result was regular for 91.2%, poor for 8.8% and excellent for 0% ($p < 0.05$). The aesthetic result was regular for 88.2%, poor for 11.8% and excellent for 0% ($p < 0.05$). The main complications were scleral exposure and temporary ocular chemosis.

Fricke's lower cheek flap is an easy-to-perform, important and often-necessary technique that, in some cases, has yielded positive functional and aesthetic results. This procedure is performed on an outpatient basis and is optimal for aged patients who present with skin cancer and who require total lower-eyelid reconstruction. The use of this technique is associated with a low complication rate and low morbidity.

* Corresponding author. Predio Canoas s/n, Col. Los Angeles, C.P. 3400, Durango, Mexico. Tel.: +52 618 8121417; fax: +52 618 8123691.
E-mail address: ronellbologna@hotmail.com (R. Bologna-Molina).

1748-6815/$ - see front matter © 2011 British Association of Plastic, Reconstructive and Aesthetic Surgeons. Published by Elsevier Ltd. All rights reserved.
doi:10.1016/j.bjps.2011.06.044

Please cite this article in press as: Barba-Gómez J, et al., Total lower-eyelid reconstruction: Modified Fricke's cheek flap, Journal of Plastic, Reconstructive & Aesthetic Surgery (2011), doi:10.1016/j.bjps.2011.06.044

Different techniques have been used to reconstruct major lower-eyelid defects, including the Mustarde flap,[1] the Hughes transposition flap, the Tenzel flap, the median forehead flap and the free tarsal flap, which is used for defects greater than 50%.[2]

Fricke's flap was initially described in 1829 by Johann Karl Fricke.[3] It is a temporally based monopedicle forehead transposition flap that can be used in the reconstruction of large lower lid, upper lid and lateral canthal defects or to bring vascularised tissue to anterior orbital defects. Its main use is for the reconstruction of defects that affect the entire length of the lower lid.

Use of the cheek donor area has the advantage of providing a greater amount of tissue without causing eyebrow elevation, in contrast to the effects of using the frontal area. This technique has been largely abandoned but has been used many times as a last resort in cases of eyelid reconstruction.[4,5]

In our work, the aesthetic and the functional results of using the modified Fricke's cheek flap (a variation of this flap taken from the cheek) for the immediate reconstruction of non-melanoma skin cancer affecting the totality of the lid surface are shown; this flap was used to resect the tumour *en bloc* without performing a chondromucous graft. Initially, a chondromucous graft taken from the nasal septum was included, but when this graft failed to take in certain patients, we observed second-intention re-epithelialisation of the posterior lamella in the second month without any notable deleterious functional or aesthetic effects in the flap, as well as preservation of the orbital mucosa. As this is a transposition flap that includes cellular subcutaneous tissue, it provides the necessary support with a lack of tension and minimal retraction in some cases, but, in other cases, the support provided was not ideal and the retraction was evident.

Methods

The medical records of 34 patients from the Dermatological Institute of Jalisco 'Dr. José Barba Rubio' and from private clinics from 1998 to 2009 were reviewed. New cases arising at the beginning of this study (2008) through December 2009 were also included. The records of those patients in which the use of Fricke's cheek flap was required for total lower-eyelid reconstruction after non-melanoma skin cancer extirpation were selected; these records include pre- and postoperative pictures, as well as follow-up ranging from months to 5 years. The patients were summoned for evaluation; the current state of those who attended was evaluated, and new pictures were taken.

The results of the technique were classified according to their functionality and cosmetic results following the criteria reported by Wilcsek et al.[4]

Function

(1) Excellent: no permanent ocular complaints.
(2) Regular: minimal functional alteration, required topical therapy.
(3) Poor: functional alterations that require surgical correction.

Cosmetics

(1) Excellent: no asymmetry or flap bulging.
(2) Regular: mild asymmetry and/or flap bulging that require no surgical intervention.
(3) Poor: major asymmetry and flap bulging that require surgical intervention.

Surgical technique

All patients had previously undergone biopsies that indicated malignancies.

The plan for tumour resection is drawn with adequate margins (the area of clinical involvement is outlined with a surgical marker, and a second ring is drawn around the tumour, marking an additional 4 mm of clinically uninvolved skin to remove). The planned donor flap is sketched vertically, being slightly longer and wider than the defect to compensate for its retraction; this flap will include the totality of the subcutaneous cellular tissue, having the SMAS as its deepest limit. The length-to-width ratio should be 4:1, although this is not a set rule and the ratio can be larger or smaller (Figure 1).

The procedure is performed with topical anaesthetic drops and local infiltration anaesthesia (lidocaine 2% with epinephrine at 1:200,000); after 10 min, the skin of the marked tumour margins, including skin, subcutaneous cellular tissue, muscle, periosteum and palpebral conjunctiva, is excised along with the tumour using the most peripheral marking with care taken to preserve the bulbar conjunctiva and the lower fornix. A suture is made to orient the tissue for the dermatopathologist. If frozen sections show residual tumour cells, we re-excise the area involved until the margins are tumour-free, and we subsequently can reconstruct the eyelid (Figure 2). Exhaustive haemostasia was performed, and dissection of the donor flap was performed with a new set of instruments. The flap can be lipectomised according to the defect; the skin surrounding the donor area is dissected to obtain greater displacement for direct closure with the least possible tension. No chondromucous grafts are used for the reconstruction of the posterior lamella (Figure 3).

Figure 1 Planning of Fricke's flap.

Please cite this article in press as: Barba-Gómez J, et al., Total lower-eyelid reconstruction: Modified Fricke's cheek flap, Journal of Plastic, Reconstructive & Aesthetic Surgery (2011), doi:10.1016/j.bjps.2011.06.044

Figure 2 En-block tumor resection extending onto the conjunctiva.

Once adequate transposition is established, the first half-buried horizontal mattress suture is placed in the apex between the donor and the receptor area (Figure 4(A)), taking it to the angle comprised by the flap and the outer border of the donor area (Figure 4(A1)). The donor area is then closed with 5/0 nylon horizontal mattress sutures. Next, the flap is fitted to the skin of the lower lid by means of simple 5/0 nylon sutures, avoiding excessive tension. Care should be taken to lipectomise the flap in the area of contact with the eyeball. No evidence of lack of mobility, synechiae or corneal ulcer has been observed (Figure 5).

Ethics

All of the procedures described here were performed in accordance with the ethical standards of the responsible committee on human experimentation at the Instituto Dermatológico de Jalisco 'Dr. José Barba Rubio' SSJ and following the Helsinki Declaration of 1975, as revised in 2000.

Figure 3 Flap dissection.

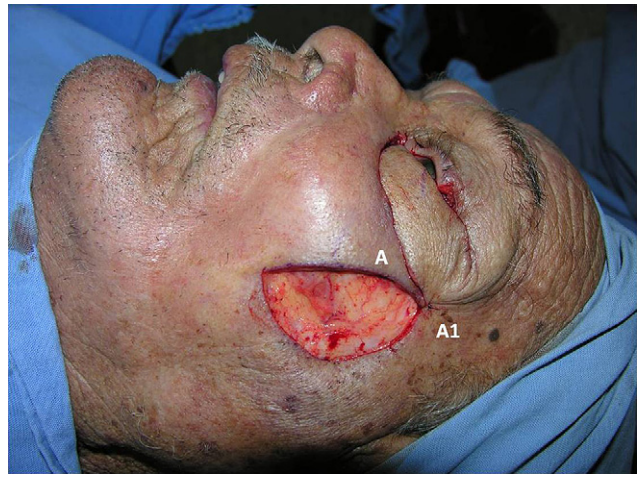

Figure 4 First connection flap point, proving its transposition.

Statistical analyses

Measures of central tendency and dispersion were calculated for the continuous variables. In the case of categorical variables, frequencies and percentages for each category were used. Non-parametric tests using Pearson's chi-square statistic for trends tried to examine the association between the range of functionality and aesthetic variables (Table 1). The results were considered significant with a $p < 0.05$. The results were tabulated and analysed using Statistical Package for Social Sciences (SPSS) 17.0 software (SPSS Professional Statistics, SPSS Inc., IL, USA).

Figure 5 Immediate postoperative results.

Please cite this article in press as: Barba-Gómez J, et al., Total lower-eyelid reconstruction: Modified Fricke's cheek flap, Journal of Plastic, Reconstructive & Aesthetic Surgery (2011), doi:10.1016/j.bjps.2011.06.044

Table 1 Aesthetic and functional results.

	Poor, *n* (%)	Regular, *n* (%)	Excellent, *n* (%)	*p*-Value
Functionality	3 (8.8%)$^{+}$	31 (91.2%)$^{++}$	0 (0%)	0.00 (+ vs. ++)[a]
Aesthetics	4 (11.8%)$^{+}$	30 (88.2%)$^{++}$	0 (0%)	0.00 (+ vs. ++)[a]

[a] χ^2 chi-square test.

Results

A total of 34 cases (30 cases diagnosed as basocellular carcinoma and four as squamous cell carcinoma) localised in the lower eyelid and affecting the totality or near-totality of the eyelid were included; these cases were treated with total reconstruction using a modified Fricke's cheek flap. The average age of the patients was 58.4 ± 12.36 years (ranging from 38 to 83): 52.9% were female and 47.1% were male (18 women and 16 men). The average follow-up time varied from months to 5 years with a mean length of 14 months.

The functional result was regular in 91.2%, poor in 8.8% and excellent in 0% of patients ($p < 0.05$). The aesthetic result was regular in 88.2%, poor in 11.8% and excellent in 0% ($p < 0.05$); see Table 1. The results after 3 months are presented in Figures 6 and 7 and after 11 months in Figure 8(a) and (b). All of the patients with regular functional results developed minimal exposure of the sclera. All of the patients developed ocular chemosis; however, this condition resolved within a 2-month period in all of the patients. We did not observe any corneal injury (corneal scarring, ulceration or perforation).

Figure 6 Results after 3 months of surgery.

In our casuistic, we observed that 27/34 (79.4%) patients developed conjunctivitis over a period of 45–63 days, which disappeared by secondary intention with re-epithelialisation of the palpebral mucosa due to the growth of ocular mucosa.

Four patients (11.4%) experienced temporary tearing, and one patient (2.8%) experienced ocular pain for 4 months.

Some complications were observed, such as dehiscence in three cases (8.5%) and distal flap necrosis in two cases (5.7%).

Discussion

There are different techniques for total or partial lower-eyelid reconstruction, such as the method described by Mustarde,[1] the Hughes[6] transposition flap with its modifications,[7] the eyelid[8] cutaneous rim graft, the hard palate graft covered by an orbicularis oculis myocutaneous advancement flap,[9] the Tripier[10] flap and more complex approaches, such as the pre-expansion mucosa-lined tongue flap,[11] the use of acellular human dermis,[12,13] the cheek flap supported by fascia lata,[14] the island tarso-conjuctival mucochondrocutaneous flap[15,16] and the use of an expanded forehead Fricke flap.[3,4,17] All of these techniques are useful when reconstruction of the lower eyelid is required; however, some of these procedures are complex and expensive.

The modified Fricke's cheek flap is a variation of this classical flap taken from the cheek. Use of the cheek donor area has the advantage of providing a greater amount of tissue adjacent to the defect, which matches the defect in terms of colour and texture. This approach also prevents elevation of the eyebrow, as occurs when taking the graft from the forehead. This technique offers a procedure without the use of mucosa graft, as our experience demonstrates that there is acceptable regeneration of the mucosa over the granulation tissue that will be formed between the flap and the ocular conjunctiva. We did not observe corneal injury (corneal scarring, ulceration or perforation) in any of our cases. In our series of patients, the palpebral rim, the palpebral conjunctiva, the lower orbicularis muscle, the subcutaneous tissue and the skin were removed (*en bloc* resection); a transposition but not a chondromucous (composed of nose and mucosa) flap was used.

The granulation tissue created at the bottom of the flap mucosilises with time, which tends to contract and tether the flap downwards, thereby increasing scleral exposure.

This procedure has some disadvantages, including temporary chemosis of the conjunctiva coming in contact with the flap and scar tissue in the cheek area. In some

Please cite this article in press as: Barba-Gómez J, et al., Total lower-eyelid reconstruction: Modified Fricke's cheek flap, Journal of Plastic, Reconstructive & Aesthetic Surgery (2011), doi:10.1016/j.bjps.2011.06.044

Figure 7 (a) Basocellular carcinoma in the lower eyelid; (b) immediate post-surgical results; and (c) results 3 months after surgery.

Figure 8 (a) Frontal view and (b) lateral view after 11 months of surgery.

cases, corneal injury may be observed, sometimes requiring further surgery for correction.

We are aware that darker skins tend to scar poorly from the aesthetic point of view. However, this technique is considered an oncological surgery in which tumour removal and functional repair are the main priorities. Special care is devoted to obtaining a pleasing aesthetic result, which can be improved with secondary interventions, such as flap lipectomy, scar revision and eyelash implants. The lamella posterior can also be reconstructed with a periosteum flap to improve the results.

We conclude that Fricke's cheek flap is an important yet simple technique for total lower-eyelid reconstruction. With this technique, the absence of mucosa graft results in certain disadvantages: support is not perfect, the results are not excellent and the reconstruction is less than optimal. However, this procedure is relatively rapid and is performed on an outpatient basis, which is optimal for aged patients, and yields a low complication rate and low morbidity. Therefore, Fricke's cheek flap represents a valuable procedure with acceptable cosmetic and functional results after the resection of non-melanoma skin cancer.

Conflict of interest

None declared.

Funding

None declared.

References

1. Mustarde JC. *Repair and reconstruction of the orbital region*. 2nd ed. Edinburgh: Churchill Livinvgstone; 1980. p. 133.

2. Chandler D, Gausas R. Lower eyelid reconstruction. *Otolaryngol Clin N Am* 2005;**38**:1033—42.
3. Fricke JCG. *Die Bildung neuer Augenlider (Blepharoplastik) nach Zerstörungen und dadurch hervorgebrachten Auswärtswendungen derselben*. Hamburg: Pethes und Bessler; 1829.
4. Wilcsek G, Leatherbarrow B, Halliwell M, et al. The "RITE" use of the Fricke flap in periorbital reconstruction. *Eye* 2005;**19**: 854—60.
5. Zoltan J. Repair of the lower eyelid with frontal and temporal flaps. Flaps taken from the cheek. In: Zoltran, editor. *Atlas Der Hautersatz Verfahren*. 1st ed. Budapest: Karger Akademiai Kiado; 1984. p. 147.
6. Hughes WL. Total lower eyelid reconstruction: technical details. *Trans Am Ophthalmol Soc* 1976;**74**:321—9.
7. Rohrich RJ, Zbar RI. The evolution of the Hughes tarsoconjunctival flap for the lower eyelid reconstruction. *Plas Reconstruc Surg* 2005;**116**:1425—30.
8. O'Donnell BA. The cutaneomarginal eyelid graft. *Exp Ophthalmol* 2002;**30**:136—9.
9. Lalonde Donald H, Osei-Tutu Kannin B. Functional reconstruction of unilateral, subtotal, full-thickness upper and lower eyelid defects with a single hard palate graft covered with advancement orbicularis myocutaneous flaps. *Plast Reconstr Sur* 2005;**115**:1696—700.
10. Herman AR, Bennet RG. Reconstruction of a large surgical defect on the lower eyelid and infraorbital cheek. *Dermatol Surg* 2005;**31**:689—91.
11. Miyawaki T, Hisako A, Suzuki H, et al. Pre-expansion of mucosa-lined flap for lower eyelid reconstruction. *Plast Reconstr Surg* 2005;**116**:76e—82e.
12. Li TG, Shorr N, Goldberg RA. Comparison of the efficacy of hard palate grafts with acellular human dermis grafts in lower eyelid surgery. *Plast Reconstr Surg* 2005;**116**:873—8.
13. Taban M, Douglas R, Li T, et al. Efficacy of "thick" acellular human dermis (AlloDerm) for lower eyelid reconstruction: comparison with hard palate and thin alloderm grafts. *Arch Facial Plast Surg* 2005;**7**:38—44.
14. Matsumoto K, Hideki Nakanishi, Urano Y, et al. Lower eyelid reconstruction with a cheek flap supported by fascia lata. *Plast Reconstr Surg* 1999;**103**:1650—4.
15. Porfiris E, Christopoulos A, Sandris P, et al. Upper eyelid orbicularis oculi flap with tarsoconjunctival island for reconstruction of full-thickness lower lid defects. *Plast Reconstr Surg* 1999;**103**:186—91.
16. Porfiris E, Georgiou P, Harkiolakis G, et al. Island mucochrondrocutaneous flap for reconstruction of total loss of the lower eyelid. *Plast Reconstr Surg* 1997;**100**:104—7.
17. Salomon J, Bieniek A, Baran E, et al. Basal cell carcinoma on the eyelids: own experience. *Dermatol Surg* 2004;**30**:257—63.

Please cite this article in press as: Barba-Gómez J, et al., Total lower-eyelid reconstruction: Modified Fricke's cheek flap, Journal of Plastic, Reconstructive & Aesthetic Surgery (2011), doi:10.1016/j.bjps.2011.06.044