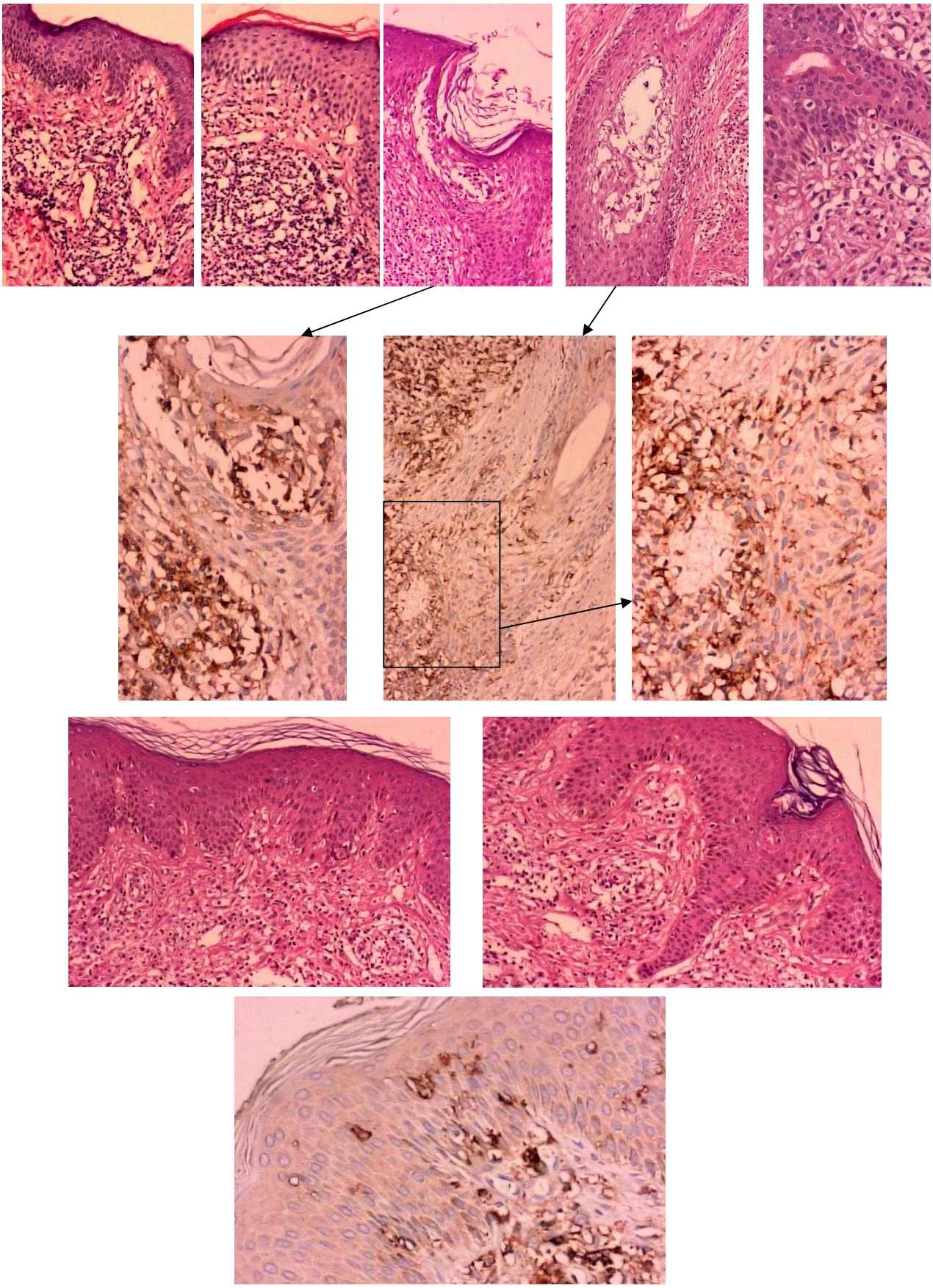H&E y CD43 del caso 225: Placa eritematosa en región glútea izquierda.