

Finasteride Treatment of Female Pattern Hair Loss

Matilde Iorizzo, MD; Colombina Vincenzi, MD; Stylianos Voudouris, MD; Bianca Maria Piraccini, MD, PhD; Antonella Tosti, MD

Objective: To evaluate the efficacy of oral finasteride therapy associated with an oral contraceptive containing drospirenone and ethinyl estradiol in premenopausal women with female pattern hair loss.

Setting: Outpatient consultation for hair disorders at the Department of Dermatology, University of Bologna.

Patients and Intervention: Thirty-seven women with female pattern hair loss were treated with oral finasteride, 2.5 mg/d, while taking an oral contraceptive containing drospirenone and ethinyl estradiol. Treatment efficacy was evaluated using global photography and the hair density score from videodermoscopy. A self-administered questionnaire was used to assess patient evaluation of treatment effectiveness.

Results: At 12-month follow-up, 23 of the 37 patients were rated as improved using global photography (12 were

slightly improved, 8 were moderately improved, and 3 were greatly improved). No improvement was recorded in 13 patients. One patient experienced worsening of the condition. There was a statistically significant ($P = .002$) increase in the hair density score in 12 patients. No adverse reactions to the drug were reported.

Conclusions: Sixty-two percent of the patients demonstrated some improvement of their hair loss with the use of finasteride, 2.5 mg/d, while taking the oral contraceptive. It is unclear whether the success was due to a higher dosage of finasteride (2.5 mg instead of 1 mg) or to its association with the oral contraceptive containing drospirenone, which has an antiandrogenic effect. Further studies are necessary to understand which patterns of female pattern hair loss respond better to this treatment.

Arch Dermatol. 2006;142:298-302

FEMALE PATTERN HAIR LOSS (FPHL), the most common form of hair loss, affects up to 50% of women during their life.¹ Although hair thinning in women with FPHL may be diffuse, 3 different clinical patterns have been described: the Christmas tree pattern,² the Ludwig pattern,³ and the Hamilton pattern.⁴ Patients who experience hair thinning complain of social anxiety and embarrassment. If left untreated, FPHL may be rapidly progressive.

Treatment for FPHL consists mainly of topical minoxidil, which is effective⁵ but sometimes is not well accepted by the patient. The efficacy of oral antiandrogens is not well established. Although cyproterone acetate is prescribed in Europe to treat FPHL,⁶⁻⁸ its efficacy is still controversial. A controlled 12-month randomized trial⁹ compared the effects of cyproterone acetate, 52 mg/d, with 2% topical minoxidil in FPHL. All the patients took oral contraceptives. After 6 months of treatment, minoxidil was effective in women with a low body mass index and the absence of hyperandrogenism. Cy-

proterone was effective when other signs of hyperandrogenism were present and when body mass index was high.

For editorial comment see page 362

In a recent study,¹⁰ treatment with oral antiandrogens (spironolactone and cyproterone and oral contraceptives in premenopausal women) produced hair regrowth in 35 (44%) of 80 women with FPHL. This study showed no relationship between response to treatment and patient age, menopausal status, and serum hormone levels. Spironolactone (100-200 mg/d) and cyproterone acetate (50-100 mg/d) produced similar results. In a small 12-month randomized trial,¹¹ flutamide was reported to be effective at 250 mg/d and was better than cyproterone acetate, 50 mg/d, and finasteride, 5 mg/d. We report herein our experience with finasteride, 2.5 mg/d, taken with an oral contraceptive containing drospirenone and ethinyl estradiol in 37 premenopausal women with FPHL.

Author Affiliations:
Department of Dermatology,
University of Bologna,
Bologna, Italy.

METHODS

STUDY PATIENTS AND DESIGN

Thirty-seven premenopausal women with FPHL seen for consultation regarding hair loss were enrolled in this study (**Table 1**). The thinning hair was not associated with increased shedding, and the pull test result was negative. Other inclusion criteria were normal androgen levels and ovulatory cycles, normal iron and ferritin levels, and negative thyroid function test results. Patients affected by acne or hirsutism were excluded.

After providing informed consent, patients were prescribed finasteride, 2.5 mg/d, and an oral contraceptive containing drospirenone, 3 mg, and ethinyl estradiol, 30 µg (Yasmin; Schering AG Germany, Berlin, Germany). All 37 women had refused to apply topical minoxidil. Camacho¹² reported good results with this finasteride dose in patients with FPHL. Finasteride treatment, which is teratogenic, requires oral contraception to prevent pregnancy. Ethinyl estradiol–drospirenone, which has antiandrogenic activity, was selected because of its possible adjuvant effect on FPHL.

EVALUATION PROCEDURES

Global photography, using a Nikon-Canfield D1 camera with a Nikon 60-mm f2.8 lens (Nikon Inc, Melville, NY), was performed at baseline and after 12 months of treatment. The patient's head was placed in a stereotactic device to ensure consistent positioning and photographic distance. Pictures obtained at 12 months were compared with those obtained at baseline and rated by one of us (M.I.), who was not involved in the clinical study. A 7-point scale was used to evaluate hair density in response to treatment¹³: -3, greatly decreased; -2, moderately decreased; -1, slightly decreased; 0, no change; 1, slightly increased; 2, moderately increased; and 3, greatly increased.

Hair density score at baseline and after 12 months was evaluated using computerized light videodermoscopy (FotoFinder dermoscope; Teachscreen Software GmbH, Bad Birnbach, Germany) with ×20 magnification lenses. Probed images were digitized and stored. To assess the hair density score, we adapted the scale proposed by de Lacharrière et al¹⁴ to our instrument. The reference scores for hair density were obtained by counting the number of hairs on 1 side from center parting within the same area at the vertex (cross between nose line and ear implantation): 1, baldness (<15 hairs); 2, very low hair density (15-20 hairs); 3, low hair density (21-30 hairs); 4, medium hair density (31-40 hairs); 5, high hair density (41-50 hairs); and 6, very high hair density (>50 hairs).

One of us (C.V.) showed the patients their photographs at baseline and at 12 months and requested that they assess the results of treatment using a self-administered questionnaire. They were questioned about their satisfaction, the appearance of their hair, the stabilization of hair loss, and the promotion of hair growth using the 7-point scale described previously herein.

STATISTICAL ANALYSIS

A *t* test for matched samples was run on hair density values to corroborate the qualitative findings.

RESULTS

The patients ranged in age from 19 to 50 years (mean, 33.7 years) (Table 1). After 12 months, 23 of the 37 patients were rated as improved using global photography

Table 1. Characteristics of 37 Women With Female Pattern Hair Loss

Patient Age, y	Baseline Clinical Pattern	12-mo GPA (-3 to +3)	Hair Density Score	
			Baseline	12 mo
39	Christmas tree	1	4	4
25	Ludwig I	2	5	6
38	Ludwig I	0	5	5
34	Christmas tree	0	5	5
24	Christmas tree	0	5	5
24	Ludwig II	2	4	5
30	Ludwig I	2	4	5
28	Ludwig I	0	4	4
22	Ludwig II	2	3	4
30	Christmas tree	1	4	4
38	Christmas tree	1	5	5
26	Ludwig I	0	5	5
29	Christmas tree	0	5	5
44	Christmas tree	0	5	5
42	Ludwig II	3	4	5
48	Ludwig I	1	5	5
42	Ludwig I	1	5	5
47	Ludwig II	2	3	4
43	Ludwig I	0	5	5
41	Ludwig I	-1	5	4
43	Ludwig I	0	5	5
34	Christmas tree	1	4	5
19	Christmas tree	2	4	5
27	Christmas tree	3	4	6
50	Ludwig I	0	5	5
30	Christmas tree	2	5	6
27	Ludwig I	1	5	5
21	Ludwig II	3	3	5
31	Christmas tree	1	5	5
25	Ludwig I	0	5	5
48	Christmas tree	1	5	5
32	Ludwig II	0	4	4
36	Christmas tree	1	5	5
36	Christmas tree	1	5	5
38	Christmas tree	1	5	5
29	Christmas tree	0	4	4
29	Christmas tree	2	4	5

Abbreviation: GPA, global photography assessment.

(12 were slightly improved, 8 were moderately improved [**Figure 1**], and 3 were greatly improved [**Figure 2**]). No improvement was recorded in 13 patients. One patient experienced worsening of the condition despite treatment. Hair density scores increased in 12 patients (**Figure 3**) from a mean density of 4.5 at baseline to 4.8 at 12 months ($t = -3.375$; $P = .002$). Using the self-administered questionnaire, 29 patients judged their condition as improved and 8 as stabilized. None of the women considered their condition worsened (**Table 2**). No patients experienced adverse reactions during treatment.

COMMENT

Finasteride is a 5α-reductase type II inhibitor currently approved to treat male androgenetic alopecia at a dosage of 1 mg/d. Because of the potential risk of teratogenicity in a male fetus,¹⁵ finasteride is contraindicated

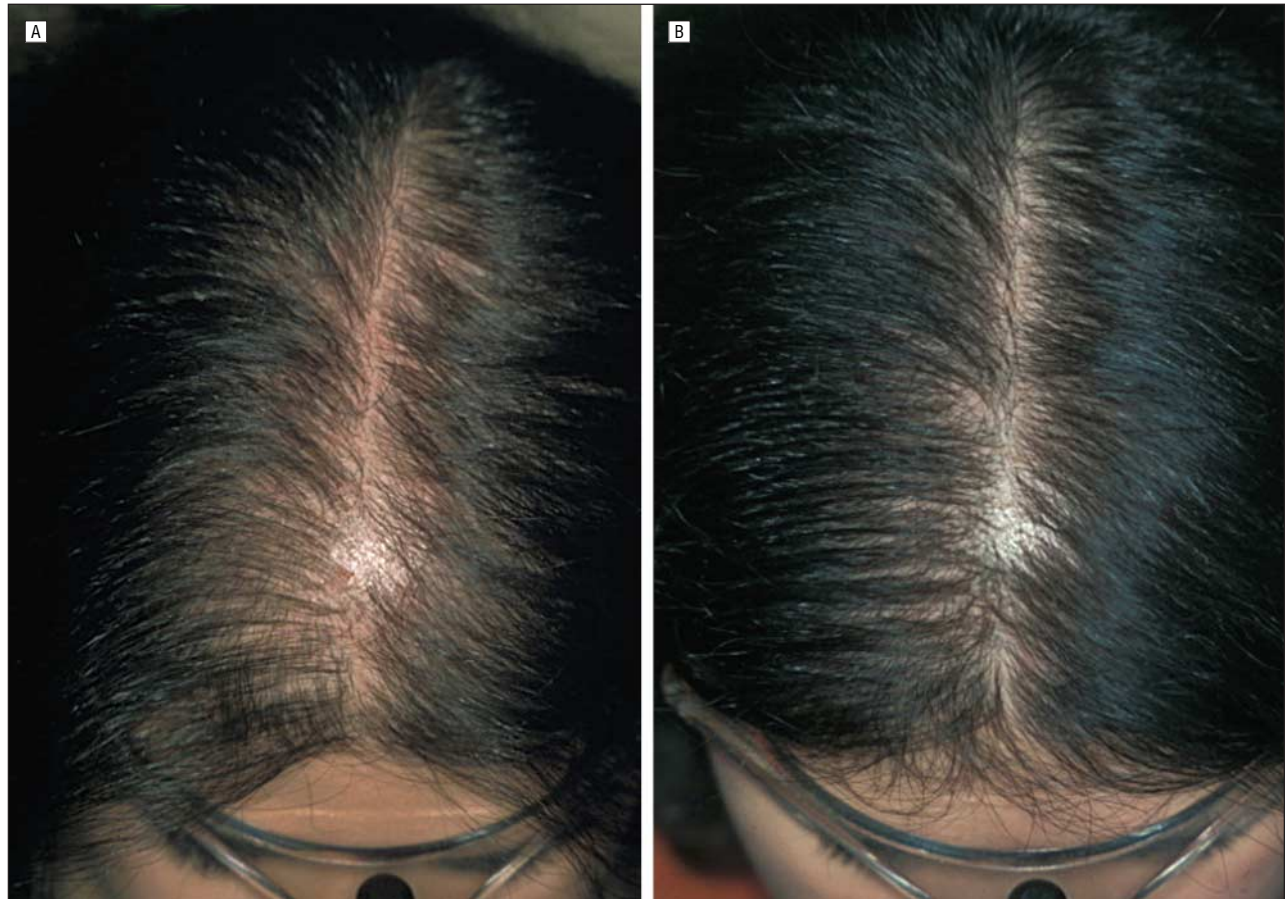


Figure 1. Christmas tree pattern of hair loss shows moderate improvement compared with baseline (A) after 12 months of oral finasteride treatment (B).

in women of childbearing potential. The efficacy of finasteride in FPHL is still controversial.

A multicenter, double-blind, placebo-controlled, randomized study¹⁶ of finasteride, 1 mg/d, in postmenopausal women with FPHL showed negative results in increasing hair growth and slowing the progression of hair thinning. After 12 months of treatment, patients in the finasteride and placebo groups had a modest decrease in hair count from baseline. Scalp biopsies also revealed no differences in the anagen-telogen ratio and the terminal hair–miniaturized hair ratio. In this study, the lack of efficacy of finasteride may have been related to the older age of the patients. Hair thinning may not be androgen dependent in senescent scalps. Moreover, in this study with negative findings, finasteride was administered at a dosage of 1 mg/d, which might be inadequate for FPHL.

Recently, noncontrolled studies^{12,17-19} indicated that finasteride therapy can be effective in premenopausal and postmenopausal women with and without signs of hyperandrogenism. Camacho¹² reported hair regrowth using finasteride, 2.5 mg/d, in 41 women with FPHL and SAHA (seborrhea, acne, hirsutism, and alopecia) syndrome. Thai and Sinclair¹⁷ administered finasteride at a dosage of 5 mg/wk (<1 mg/d) to a 67-year-old postmenopausal woman without signs of hyperandrogenism and with Ludwig FPHL. After 12 months of treatment the patient showed a significant increase in hair density. Shum et al¹⁸ administered finasteride to 4 women

with hyperandrogenism at a dosage of 1.25 mg/d. Two of these patients had a Ludwig-type FPHL, and the other 2 had a Hamilton pattern. Only 2 of the women were postmenopausal, but the others had a history of infertility with irregular menses. Increased hair growth and decreased progression of hair loss were observed in all the patients after 6 months and 1, 2, and 2.5 years of treatment, respectively. The efficacy of finasteride in postmenopausal normoandrogenic women with FPHL was reported by Trueb¹⁹ as early as after 6 months of treatment. Finasteride was administered at 2.5 mg/d in 4 women, 1 with the Christmas tree pattern and 3 with the Ludwig pattern, and finasteride, 5 mg/d, in 1 woman with the Hamilton pattern.

A recent case report²⁰ also indicated that the dual 5 α -reductase inhibitor dutasteride, 0.5 mg/d, can improve FPHL. All these studies of oral antiandrogens in premenopausal women with FPHL used oral contraception to prevent pregnancy. However, different contraceptives were used, and information about a possible effect of these agents on treatment efficacy is lacking.

In the present study, 62% of patients demonstrated some improvement of their hair loss after 1 year of treatment with finasteride, 2.5 mg/d, taken with an oral contraceptive containing drospirenone and ethinyl estradiol (32% slightly improved, 22% moderately improved, and 8% greatly improved). Finasteride was well tolerated compared with the other oral antiandrogens, and

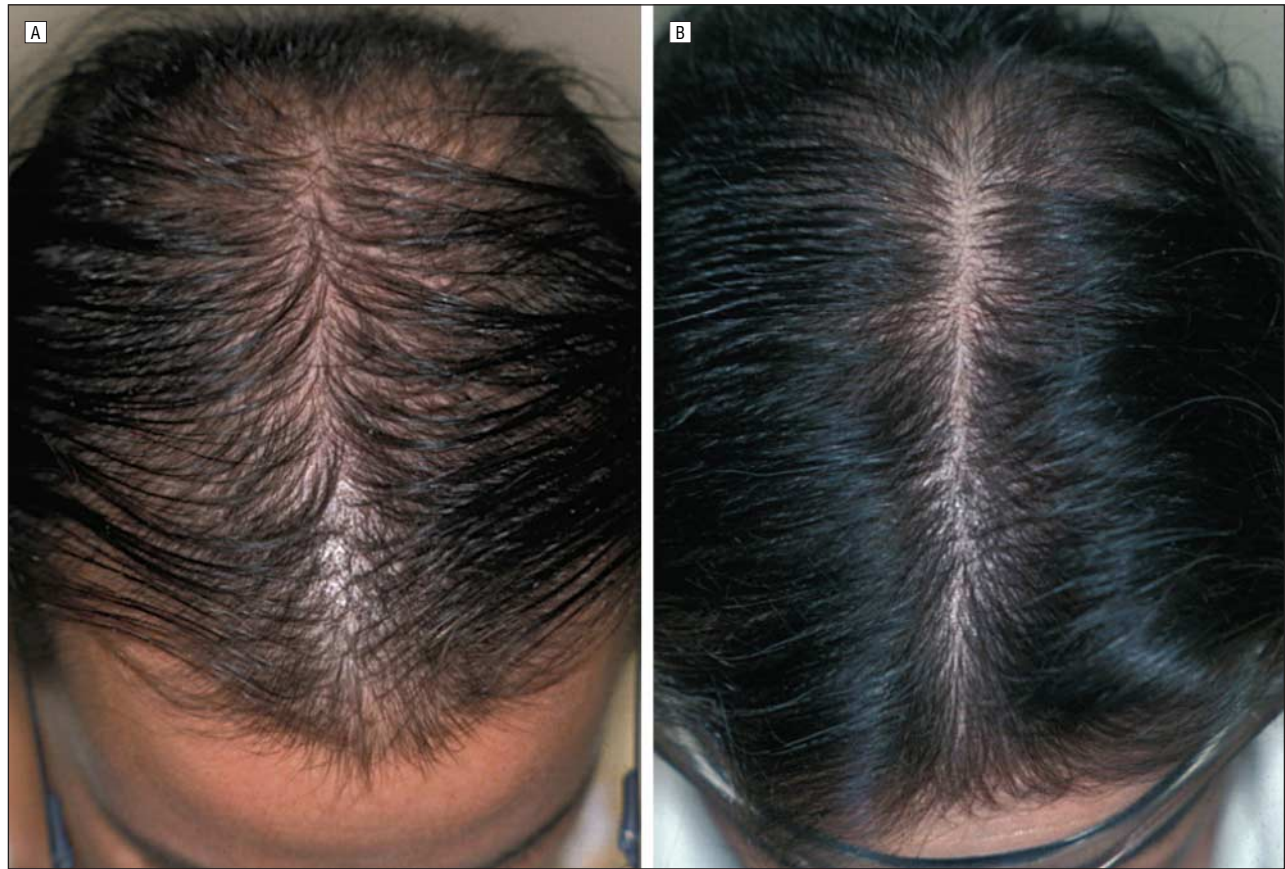

Figure 2. Ludwig pattern of hair loss shows great improvement compared with baseline (A) after 12 months of oral finasteride treatment (B).

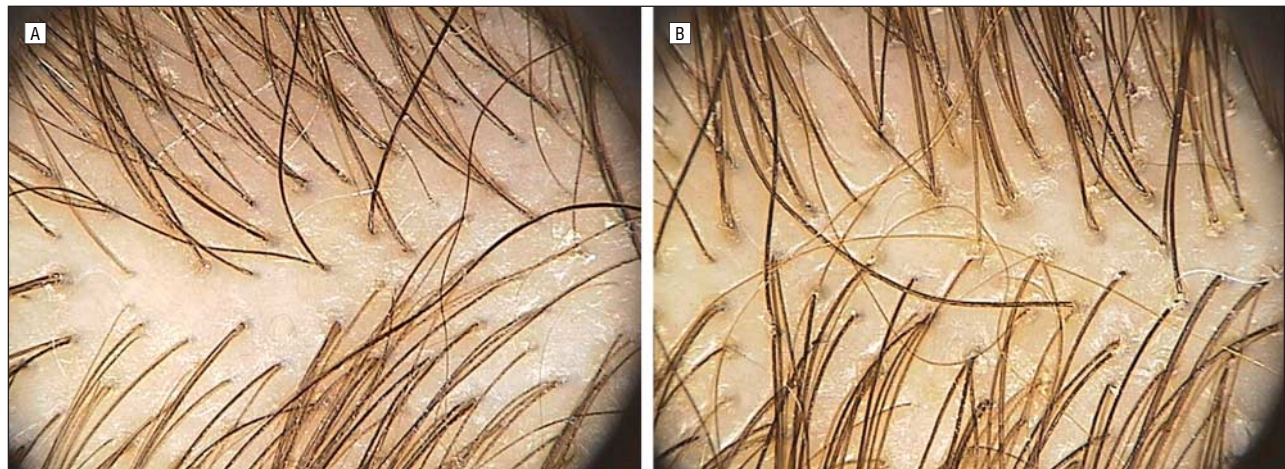

Figure 3. Improvement in the hair density score compared with baseline (A) at 12 months of oral finasteride treatment (B).

none of the patients reported adverse effects. This treatment was well accepted by the patients, who judged the results to be even better than did the investigators. The patient's opinion being generally more optimistic than that of the investigator is not surprising. In double-blind clinical trials on the efficacy of finasteride on male androgenetic alopecia,¹³ patients treated with placebo reported improvement of their condition.

The efficacy of finasteride in two thirds of our premenopausal women may be due to the higher dosage used. The contraceptive contains drospirenone, a progestin ana-

log of spironolactone. It is possible that even at a very low dosage (3 mg), drospirenone might have had an additional effect in promoting hair growth. Owing to its antiandrogenic and diuretic activities, this pill may be useful for FPHL, but it is also well accepted because it provides weight stability or even loss.²¹ The potential risk of teratogenicity of finasteride in women with childbearing potential requires oral contraception. We used the same contraception in all the patients to avoid the confounding role of contraceptive pills containing progestins with possible androgenic activity.

Table 2. Patient and Investigator Assessments of FPHL After 12 Months of Treatment*

	Patient Assessment (Questionnaire)	Investigator Assessment (GPA)
Improvement (+1, +2, +3)	29	23
Stabilization (0)	8	13
Worsening (-1, -2, -3)	None	1

Abbreviations: FPHL, female pattern hair loss; GPA, global photography assessment.

*Data are given as numbers.

Although our study is not randomized, blinded, and placebo controlled and does not include scalp biopsies, the clinical results using global photography, hair density scores, and patient self-assessment provide a basis for future work. Further studies are needed to establish the optimal dosage and mode of administration of finasteride in premenopausal women and to definitively assess the efficacy of this drug compared with oral antiandrogens.

Accepted for Publication: November 1, 2005.

Correspondence: Antonella Tosti, MD, Department of Dermatology, University of Bologna, Via Massarenti, 1-40138 Bologna, Italy (tosti@med.unibo.it).

Author Contributions: *Study concept and design:* Iorizzo and Tosti. *Acquisition of data:* Voudouris. *Analysis and interpretation of data:* Iorizzo, Vincenzi, and Tosti. *Drafting of the manuscript:* Iorizzo, Piraccini, and Tosti. *Critical revision of the manuscript for important intellectual content:* Iorizzo and Tosti. *Study supervision:* Iorizzo and Tosti.

Financial Disclosure: None.

Acknowledgment: We thank Gabriella Fabbrocini, MD, University of Naples (Naples, Italy), for statistical analysis.

REFERENCES

- Price VH. Androgenetic alopecia in women. *J Invest Dermatol Symp Proc.* 2003; 8:24-27.
- Olsen EA. Female pattern hair loss. *J Am Acad Dermatol.* 2001;45:S70-S80.
- Ludwig E. Classification of the types of androgenetic alopecia (common baldness) occurring in female sex. *Br J Dermatol.* 1977;97:247-254.
- Venning VA, Dawber RP. Patterned androgenetic alopecia in women. *J Am Acad Dermatol.* 1988;18:1073-1077.
- Price VH, Menefee E. Quantitative estimation of hair growth, I: androgenetic alopecia in women: effect of minoxidil. *J Invest Dermatol.* 1990;95:683-687.
- Dawber RPR, Sonnex T, Ralfs I. Oral antiandrogen treatment of common baldness in women [abstract]. *Br J Dermatol.* 1982;107(suppl 22):20.
- Mortimer CH, Rushton H, James KC. Effective medical treatment of common baldness in women. *Clin Exp Dermatol.* 1984;9:342-350.
- Peereboom-Wynia JD, van der Willigen AH, van Joost T, Stolz E. The effect of cyproterone acetate on hair roots and hair shafts diameter in androgenetic alopecia in females. *Acta Derm Venereol.* 1989;69:395-398.
- Vexiau P, Chaspoux C, Boudou P, et al. Effects of minoxidil 2% vs cyproterone acetate treatment on female androgenetic alopecia: a controlled, 12-month randomized trial. *Br J Dermatol.* 2002;146:992-999.
- Sinclair R, Wewerinke M, Jolley D. Treatment of female pattern hair loss with oral antiandrogens. *Br J Dermatol.* 2005;152:466-473.
- Carmina E, Lobo RA. Treatment of hyperandrogenic alopecia in women. *Fertil Steril.* 2003;79:91-95.
- Camacho F. Hirsutismo: enfoque clinico terapéutico. *Acta Terap Dermatol.* 2001; 24:190-206.
- Kaufman KD, Olsen EA, Whiting D, et al. Finasteride in the treatment of men with androgenetic alopecia. *J Am Acad Dermatol.* 1998;39:578-588.
- de Lacharrière O, Deloche C, Misciali C, et al. Hair diameter diversity. *Arch Dermatol.* 2001;137:641-646.
- Prahalada S, Tarantal AS, Harris GS, et al. Effects of finasteride, a type 2 5 α -reductase inhibitor, on fetal development in the rhesus monkey (*Macaca mulatta*). *Teratology.* 1997;55:119-131.
- Price VH, Roberts JL, Hordinsky M, et al. Lack of efficacy of finasteride in postmenopausal women with androgenetic alopecia. *J Am Acad Dermatol.* 2000; 43:768-776.
- Thai KE, Sinclair R. Finasteride for female androgenetic alopecia. *Br J Dermatol.* 2002;147:812-813.
- Shum KW, Cullen DR, Messenger AG. Hair loss in women with hyperandrogenism: four cases responding to finasteride. *J Am Acad Dermatol.* 2002;47:733-739.
- Trueb RM. Finasteride treatment of patterned hair loss in normoandrogenic postmenopausal women. *Dermatology.* 2004;209:202-207.
- Olszewska M, Rudnicka L. Effective treatment of female androgenic alopecia with dutasteride. *J Drugs Dermatol.* 2005;4:637-640.
- Batur P, Elder J, Mayer M. Update on contraception: benefits and risks of the new formulations. *Cleve Clin J Med.* 2003;70:681-696.