

# Nail Lichen Planus in Children

## Clinical Features, Response to Treatment, and Long-term Follow-up

Antonella Tosti, MD; Bianca Maria Piraccini, MD; Stefano Cambiaghi, MD; Matilde Jorizzo, MD

**Objective:** To report clinical features, response to treatment, and long-term follow-up of nail lichen planus in children.

**Design:** Retrospective study involving 15 children with nail lichen planus.

**Setting:** Outpatient consultation for nail disorders at the Department of Dermatology of the University of Bologna, Bologna, Italy.

**Patients or Other Participants:** We diagnosed nail lichen planus in 15 children younger than 12 years, including 10 children with typical nail matrix lesions, 2 children with 20-nail dystrophy (trachyonychia), and 3 children with idiopathic atrophy of the nails. Only 2 of the 15 children had oral lichen planus; none had cutaneous lesions. A nail biopsy confirmed the diagnosis in all cases.

**Intervention:** Intramuscular triamcinolone acetonide, 0.5 to 1 mg/kg per month, was prescribed to children with

typical nail lichen planus and prolonged from 3 to 6 months until the proximal half of the nail was normal. No treatment was prescribed to patients with 20-nail dystrophy or idiopathic atrophy of the nails.

**Results:** Treatment with systemic corticosteroids was effective in curing typical nail lichen planus. Two children experienced a recurrence of the disease during the follow-up. Recurrences were always responsive to therapy. The 2 children with 20-nail dystrophy improved without any therapy. Nail lesions caused by idiopathic atrophy of the nails remained unchanged during the follow-up period.

**Conclusions:** Nail lichen planus in children is not rare but probably underestimated. It often presents with atypical clinical features such as 20-nail dystrophy or idiopathic atrophy of the nails.

*Arch Dermatol.* 2001;137:1027-1032

**N**AIL LICHEN planus (NLP) is considered very rare in children, with only 15 biopsy-proved cases reported in the literature, most as single case reports.<sup>1-11</sup> This number drops to 7 cases if we only consider children with typical NLP and not children with NLP producing atypical clinical features, such as 20-nail dystrophy<sup>1,4,6,10</sup> or idiopathic atrophy of the nails.<sup>2</sup> Our experience, however, indicates that NLP in children may not be that rare.

In fact, since 1986, we have diagnosed NLP in 92 patients, including 10 children younger than 12 years who attended the outpatient consultation for nail disorders of the Department of Dermatology of the University of Bologna, Bologna, Italy. These include 1 child who was previously described.<sup>11,12</sup> During this period, we examined 2928 patients with nail disorders, 147 of them younger than 12

years. We also treated and followed up 5 children with NLP who were first diagnosed at the Department of Pediatric Dermatology of the University of Milan, Milan, Italy. The 5 children represent the only cases of NLP diagnosed among 12 000 children with skin disorders seen in Milan in 3 years. We report herein the clinical features, response to treatment, and long-term follow-up of these 15 children.

### CLINICAL FEATURES

Typical NLP was diagnosed in 10 cases, 20-nail dystrophy (trachyonychia) in 2 cases, and idiopathic atrophy of the nails in 3 cases.

#### Typical NLP

Clinical criteria for diagnosis of NLP were nail plate thinning with longitudinal ridging and fissuring, with or without pte-

*From the Department of Dermatology, University of Bologna, Bologna, Italy (Drs Tosti, Piraccini, and Jorizzo); and Institute of Dermatological Science, Istituto di Ricovero e Cura a Carattere Scientifico Policlinico, University of Milan, Milan, Italy (Dr Cambiaghi).*

**Clinical Data and Response to Treatment in 15 Children With Nail Lichen Planus\***

Patient No./ Sex/Age, y	Duration	Other Diseases	Affected Nails	LP at Other Sites	Severity (1-4)	Clinical Manifestations	Response to Treatment (Fingernails)	Follow-up, y	Outcome
<b>Typical Nail LP</b>									
1/M/12	2 mo	None	1 LF, 2 LF, 5 RF, 1 LT	None	2	Longitudinal ridging and splitting	Cure after 8 mo	4	No relapses
2/M/11	10 mo	Alopecia areata, thyroiditis	All fingernails	None	2	Longitudinal ridging and splitting, onycholysis	Cure after 6 mo	3	No relapses
3/F/11	9 y	Psoriasis	20 Nails	None	1	Longitudinal ridging and splitting	Improvement after 7 mo	NA	NA
4/F/12	5 y	None	20 Nails	None	4	Longitudinal ridging and splitting, onycholysis	Cure after 9 mo	5	No relapses
5/M/7	2 y	Thyroiditis	1 RT, all fingernails	Oral	4	Longitudinal ridging and splitting, pterygium, onycholysis	Cure after 6 mo	8	Relapse, 7 y; O 1 RT
6/M/11	2 mo	None	1 RT, 1 LT, all fingernails	Oral	3	Longitudinal ridging and splitting, onycholysis	Cure after 6 mo	10	O 1 RT
7/M/8	3 mo	None	All fingernails	None	1	Longitudinal ridging and splitting	Cure after 7 mo	3	No relapses
8/F/6	2 y	None	All fingernails	None	1	Onycholysis and red lunulae	Cure after 9 mo	2	Relapse, 1 y
9/M/6	7 mo	Atopic dermatitis	1 LT, 1 RT, all fingernails	None	3	Longitudinal ridging and splitting	Cure after 8 mo (Cushing/ atrophy)	NA	NA
10/M/10	18 mo	Alopecia areata, lichen sclerosus	20 Nails	None	4	Longitudinal ridging and splitting, onycholysis	Cure after 7 mo (atrophy)	1	No relapses
<b>20-Nail Dystrophy (Trachyonychia)</b>									
1/M/9	2 y	None	20 Nails	None	3	Nail roughness, thinning	Not applicable	4	Improved
2/M/12	3 y	None	20 Nails	None	2	Nail roughness, thinning	Not applicable	6	Cured
<b>Idiopathic Atrophy of the Nails</b>									
1/M/8	5 y	None	20 Nails	None	4	Nail atrophy with and without pterygium	Not applicable	7	Unchanged
2/M/9	1 y	None	20 Nails	None	4	Nail atrophy with and without pterygium	Not applicable	6	Unchanged
3/F/12	1 y	None	20 Nails	None	4	Nail atrophy with and without pterygium	Not applicable	NA	NA

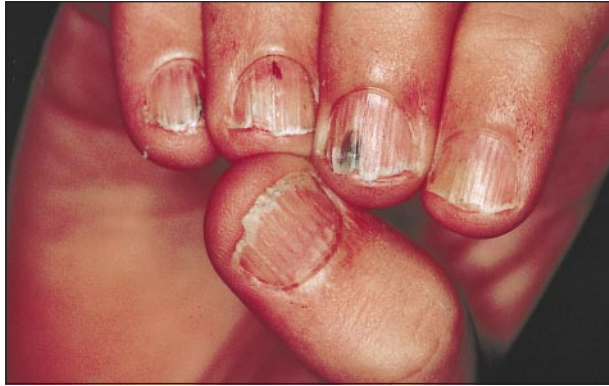\*LP indicates lichen planus; LF, left fingernail; RF, right fingernail; LT, left toenail; RT, right toenail; O, onychomycosis; and NA, not applicable.

rygium. The clinical diagnosis was always confirmed by pathological examination.

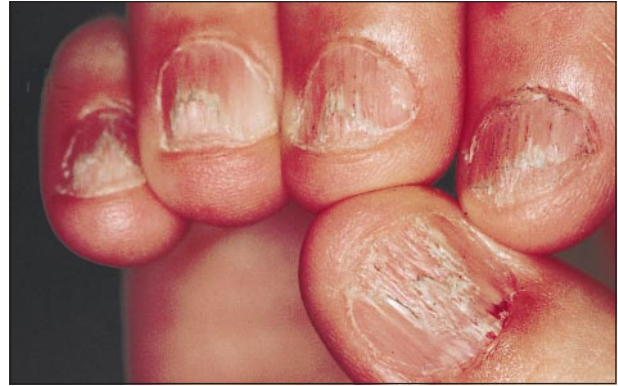Typical NLP was diagnosed in 7 boys and 3 girls, aged 6 to 12 years (mean, 9.4 years) (**Table**). The mean duration of the disease before diagnosis was 3 years (range, 2 months to 9 years). The age of the children at the time of onset of the disease ranged from 2 to 12 years. All but 1, who had just 4 nails affected, presented with diffuse nail involvement. In 3 patients, NLP involved all 20 nails and in 6 patients all the fingernails; in 3 of these 6 patients, involvement of 1 or both big toenails was also present.

In 9 patients, the affected nails showed evident thinning associated with longitudinal ridging, fissuring, and distal splitting (**Figure 1** and **Figure 2**). One patient had

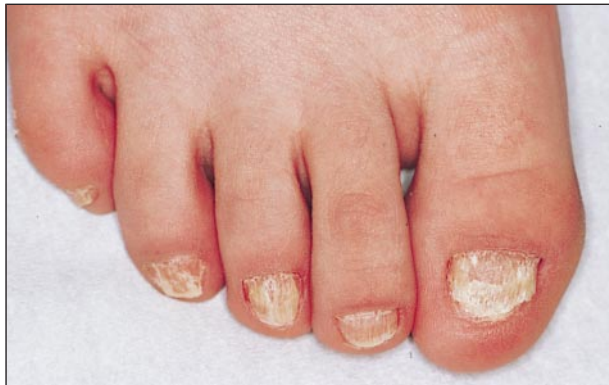red lunulae indicating distal matrix inflammation. Nail pterygium was present only in 1 big toenail of a 7-year-old child. Involvement of the nail bed with onycholysis was associated with nail matrix lichen planus (LP) in 6 children (**Figure 3**). In accordance with a subjective severity score performed by evaluating the degree of thinning and splitting, 3 patients were rated as having very severe NLP, 2 as severe, 2 as moderate, and 3 as mild. The NLP was not associated with itching or pain in any of our patients. None of them had a history of drug intake before the onset of NLP. There was no family history of LP. A stressful event (car accident) before the onset of the disease was reported by an 11-year-old boy (patient 6) who was also a member of a swimming team. None of our chil-



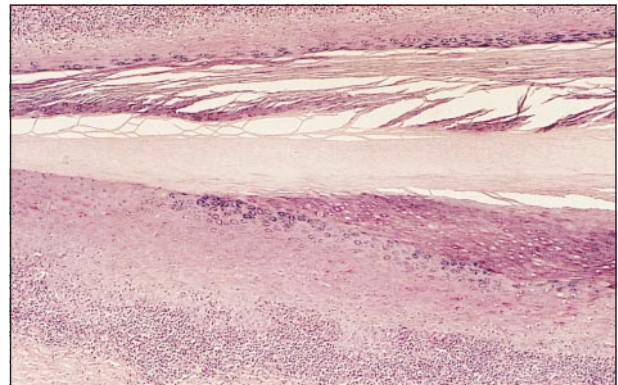
**Figure 1.** Nail lichen planus in an 8-year-old boy (patient 7). The nail plate is thinned and shows mild longitudinal ridging with distal splitting. Nail bed involvement with onycholysis is also present.



**Figure 3.** Nail lichen planus in a 12-year-old girl (patient 4). Note severe nail matrix involvement of the thumb with onychorrhexis and partial nail plate destruction. The other digits show mild ridging caused by matrix involvement and distal onycholysis caused by nail bed involvement.



**Figure 2.** Nail lichen planus in a 10-year-old boy (patient 10). The toenails show nail thinning with longitudinal striations caused by severe nail matrix involvement.



**Figure 4.** Longitudinal nail biopsy specimen showing a typical lichenoid infiltrate of the nail matrix. The keratogenous zone is replaced by a granular layer (hematoxylin-eosin, original magnification  $\times 100$ ).

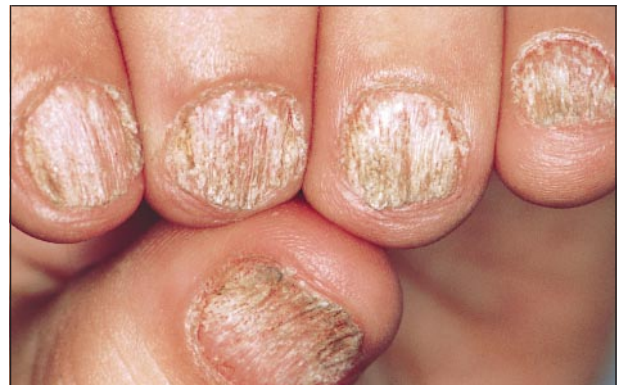dren had skin lesions of LP at the time of diagnosis or at any time during the follow-up. A mild and localized oral reticular LP was detected on mouth inspection in 2 children. Associated dermatologic conditions included patchy alopecia areata in 2 patients, psoriasis in 1, atopic dermatitis in 1, and lichen sclerosus and atrophicus in 1. Two patients had a diagnosis of autoimmune thyroiditis and were taking thyroid hormone supplementation.

Testing for antinuclear antibodies was negative in the 5 children with typical NLP who underwent this test.

A nail biopsy specimen confirmed NLP in all cases, showing a bandlike lymphocytic infiltrate of the nail matrix and/or nail bed dermis together with hyperkeratosis, hypergranulosis, and acanthosis of the nail matrix epithelium (**Figure 4**).

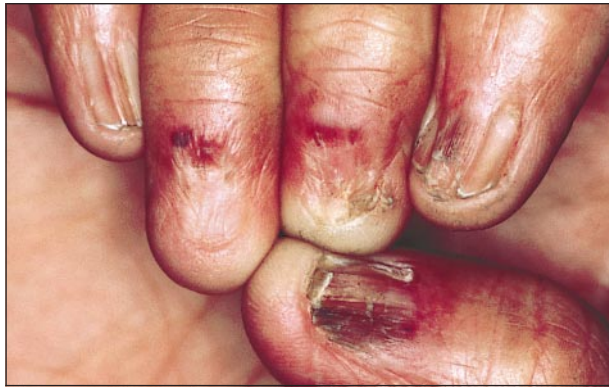#### NLP Presenting as 20-Nail Dystrophy (Trachyonychia)

Twenty-nail dystrophy (trachyonychia) is a clinical entity characterized by nail roughness caused by excessive longitudinal ridging. The condition may involve all 20 nails or be limited to 1 or several digits. Since 1986, we have obtained biopsy specimens from 13 children with 20-nail dystrophy and diagnosed 2 cases of NLP among them. The pathological findings of the other 11 cases showed spongiotic changes in 10 and psoriasis in 1.



**Figure 5.** Twenty-nail dystrophy (trachyonychia) caused by lichen planus in a 9-year-old boy.

The 2 boys with LP, aged 9 and 12 years, presented with trachyonychia involving all 20 nails. The nail lesions had appeared 2 and 3 years earlier. The nails showed mild thinning associated with nail plate roughness caused by excessive longitudinal striations (**Figure 5**). Both children were in good health and showed no other dermatologic disorders. Family history was negative for LP and alopecia areata. A longitudinal biopsy specimen from the second toenail in both cases showed the typical features of nail matrix LP, ie, acanthosis, hypergranulosis, and a



**Figure 6.** Idiopathic atrophy of the nails in a 12-year-old Indian girl.

bandlike lymphocytic infiltrate with vacuolar degeneration of basal keratinocytes.

### NLP Presenting as Idiopathic Atrophy of the Nails

Diagnosis of idiopathic atrophy of the nails was based on the presence of atrophy of several nails with absence of the nail plate with and without pterygium.

Two boys and 1 Indian girl, aged 8, 9, and 12 years, presented with severe atrophy involving all 20 nails. The clinical history was similar in all cases: the nail lesions had suddenly appeared and progressed very quickly, producing complete or partial nail destruction in 6 to 12 months. The process, which had been completely asymptomatic, had started when the children were 3, 8, and 11 years old. All patients were otherwise in good health and had no other cutaneous or mucosal signs of LP. Family history was negative for LP. At the clinical examination, the nails showed areas of scarring with pterygium and areas of severe nail thinning without obliteration of the proximal nail fold. Pterygium was partially hyperpigmented in the Indian girl (**Figure 6**). All 3 patients underwent longitudinal toenail biopsy; the specimens were taken from an area of nail thinning with preservation of the proximal nail fold. The pathological examination showed nail matrix hypergranulosis with complete disappearance of the keratogenous zone. One specimen also demonstrated a mild bandlike superficial lymphocytic infiltrate in the dermis of the proximal nail fold.

### TREATMENT

#### Typical NLP

Patients were treated with intramuscular triamcinolone acetonide (0.5-1 mg/kg every 30 days). Treatment was prolonged until the proximal half of the nail was normal. Duration of treatment ranged from 3 to 6 months. Nine children were completely cured and 1 child improved considerably with treatment. Complete cure with clinically normal fingernails occurred 6 to 8 months after the beginning of therapy (**Figure 7**). Toenails required 8 to 12 months for complete cure. Adverse effects were noticed in 2 patients, both taking higher doses of triamcinolone acetonide (1 mg/kg per month). These included lipoatrophy at the site of injections (in 2) and

cushingoid facies (in 1). Seven of our 10 children were followed up for more than 2 years (follow-up, 2-10 years; mean, 5 years). In 2 of them, NLP recurred during the follow-up period. Recurrences were observed 2 and 7 years after the initial diagnosis and responded well to systemic corticosteroid administration. The other 5 children did not experience relapses of NLP during the follow-up and did not develop LP in other skin or mucosal sites.

Two of the children (patients 5 and 6) developed a distal subungual onychomycosis caused by *Trichophyton rubrum* during the follow-up period. This was diagnosed 1 and 5 years after cure of NLP. In both cases, onychomycosis involved a big toenail that had previously been affected by LP but had recovered without residual dystrophies. Treatment with systemic antifungal agents produced complete cure of onychomycosis in both patients.

### NLP Presenting as 20-Nail Dystrophy (Trachyonychia)

The 2 children with NLP presenting as trachyonychia were not given any therapy. The follow-up (4 and 6 years) showed spontaneous improvement of the nail abnormalities in one and complete clearing in the other.

### NLP Presenting as Idiopathic Atrophy of the Nails

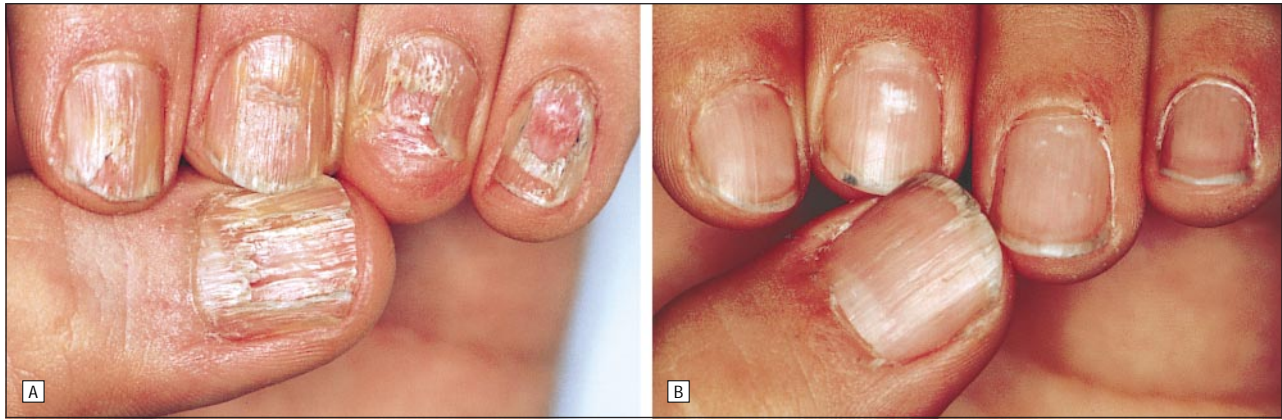The 3 children with NLP presenting as idiopathic atrophy were not given any therapy. In 2 cases, long-term follow-up showed that the nail lesions were unchanged after 6 and 7 years.

### COMMENT

Our series indicates that NLP in children is not as rare as that estimated in the literature. In fact, according to our data, 11% of patients with NLP (10/92) attending our nail consultation were younger than 12 years. Prevalence of NLP in children therefore seems higher than that of skin LP, where only 2% to 3% of patients are reported to be children.<sup>13</sup> Both NLP and skin LP appear to be more common in boys than in girls. It is interesting that in all of our children the nails were the prominent location of the disease and the sole reason for medical consultation. Therefore, it is conceivable that NLP in children is underestimated for 2 main reasons: (1) lack of skin or mucosal lesions, making the clinical diagnosis difficult for pediatricians or dermatologists not skilled in nail disorders; and (2) general reluctance to perform nail biopsies in children.

From a clinical point of view, LP of the nails in children may have 3 different presentations, each characterized by its own evolution and outcome: typical NLP, 20-nail dystrophy, and idiopathic atrophy of the nails.

In most cases, NLP in children presents with the clinical features that characterize typical NLP of adults,<sup>8,14</sup> namely, diffuse nail ridging, thinning, splitting, and dorsal pterygium. This clinical variety of NLP is caused by severe lichenoid infiltration of the nail matrix and, if not treated, may produce nail matrix destruction with scarring in both adults and children.<sup>3,7,11,15</sup>



**Figure 7.** A, Nail lichen planus in a 7-year-old boy (patient 5). Severe nail matrix involvement with nail plate thinning, fissuring, and splitting. B, Complete cure 6 months after the beginning of treatment with triamcinolone acetonide, 0.5 mg/kg every 30 days.

Although the clinical features are highly suggestive, pathological examination is required to confirm the diagnosis. Differential diagnosis includes nail changes caused by graft-vs-host disease, lichenoid drug reactions, nail scarring after Stevens-Johnson syndrome, nail matrix trauma, and lupus erythematosus.<sup>16</sup>

The second form of presentation of NLP in children is 20-nail dystrophy. This condition, also known as trachyonychia, describes a spectrum of nail plate surface abnormalities that result in nail roughness.<sup>17</sup> Twenty-nail dystrophy differs from typical NLP because of its monomorphic appearance, ie, the longitudinal ridging affects the nail plate surface uniformly, and the absence of longitudinal splitting and pterygium. Twenty-nail dystrophy may be caused by several inflammatory diseases that disturb nail matrix keratinization, such as LP, psoriasis, eczema, pemphigus vulgaris, and alopecia areata. There are no clinical criteria that distinguish spongiotic trachyonychia, the most common type (which is often associated with alopecia areata), from trachyonychia caused by other inflammatory skin diseases.

Among the 60 patients with 20-nail dystrophy subjected to nail biopsy described in the literature, only 10 were pathologically diagnosed as having NLP.<sup>17-19</sup> Twenty-nail dystrophy is a benign condition that never produces nail scarring.

The third variety of NLP is idiopathic atrophy of the nails. This scarring atrophic variant of NLP is more common in Indians and is characterized by a very acute and rapid course that leads to diffuse painless nail destruction in a few months.<sup>20,21</sup> In all the reported cases of idiopathic atrophy of the nails, the disease occurred in children.<sup>2,20,21</sup> Idiopathic atrophy of the nails differs from typical LP with pterygium formation in its acute course with scarring of most nails and in the association of nail absence caused by pterygium formation and nail absence caused by nail plate destruction without pterygium. Differential diagnosis of idiopathic atrophy of the nails includes hereditary anonychia, impaired peripheral circulation, and epidermolysis bullosa.<sup>20</sup>

It is important that NLP presenting as 20-nail dystrophy or as idiopathic atrophy of the nails is much more common in children than in adults. In fact, at the Bologna nail center, NLP presented as typical LP in 5 (50%)

of 10 children and 76 (93%) of 82 adults, as 20-nail dystrophy in 2 (20%) of 10 children and 4 (5%) of 82 adults, and as idiopathic atrophy of the nails in 3 (30%) of 10 children and 2 (2%) of 82 adults. These 2 adults, however, had both been affected by idiopathic atrophy of the nails since childhood.

Although all of our children with typical NLP had nail matrix involvement, destruction of the nail matrix with pterygium was detected in only 1 child, even though at least 5 children had been affected by the disease for more than 1 year at the time of diagnosis.

Pterygium formation is therefore rare in children with NLP and does not correlate with disease duration. An exception to this rule is represented by NLP producing idiopathic atrophy of the nails, which is almost exclusively described in children and is responsible for complete destruction of the matrix. Idiopathic atrophy of the nails is thus a distinct variety of NLP characterized by a very rapid and destructive evolution.<sup>2,21</sup> The opposite applies for LP presenting as 20-nail dystrophy, which should be considered a very mild and benign form of NLP that does not produce scarring and may regress spontaneously.<sup>17</sup>

Thirty percent of our children with NLP were affected by other immunologic skin or systemic disorders, such as alopecia areata, psoriasis, and thyroiditis. This contrasts with our findings in adults, in whom NLP is not usually associated with immunologic disorders.<sup>12</sup> Skin or mucosal involvement by LP, on the other hand, appears to be more rare in children (2/15 [13.3%]) than in adults, in whom we found extranail lesions in 25% of patients. This confirms the observation that nail involvement does not occur in children with skin LP, as none of the 50 children with skin LP described by Sharma and Maheshwari<sup>22</sup> had nail lesions.

All of our children with typical NLP responded well to treatment with systemic corticosteroids. Our experience indicates that intramuscular triamcinolone acetonide at the dosage of 0.5 mg/kg per month is an effective and safe treatment for children with NLP. Systemic triamcinolone was also successful in treating the 2 patients who had relapses of NLP during the follow-up.

Since the aim of treatment is to prevent scarring, systemic corticosteroids are useless in established idio-

pathic atrophy of the nails. Unfortunately, we never diagnosed this condition at the time of onset and therefore do not know whether corticosteroid treatment might have prevented nail matrix destruction.

Although onychomycosis is very uncommon in children, 2 (13%) of our 15 children developed toenail distal subungual onychomycosis caused by *T rubrum* after cure of NLP. None of them had a family history of onychomycosis. It is possible that corticosteroid treatment may have predisposed patients to fungal invasion.

Accepted for publication February 28, 2001.

Corresponding author and reprints: Antonella Tosti, MD, Department of Dermatology, University of Bologna, Via Massarenti 1, 40138 Bologna, Italy (e-mail: tosti@almadns.unibo.it).

## REFERENCES

1. Taniguchi S, Kutsuna H, Tani Y, Kawahira K, Hamada T. Twenty-nail dystrophy (trachyonychia) caused by lichen planus in a patient with alopecia universalis and ichthyosis vulgaris. *J Am Acad Dermatol*. 1995;33:903-905.
2. Colver GB, Dawber RPR. Is childhood idiopathic atrophy of the nails due to lichen planus? *Br J Dermatol*. 1987;116:709-712.
3. Kanwar AS, Govil DC, Singh OP. Lichen planus limited to the nails. *Cutis*. 1983;32:163-165.
4. Silverman RA, Rhodes AR. Twenty nail dystrophy of childhood: a sign of localized lichen planus. *Pediatr Dermatol*. 1984;1:207-210.
5. Scott MJ Jr, Scott MJ Sr. Ungual lichen planus. *Arch Dermatol*. 1979;115:1197-1199.
6. Scher RK, Fischbein R, Ackerman AB. Twenty-nail dystrophy: a variant of lichen planus. *Arch Dermatol*. 1978;114:612-613.
7. Burgoon CF, Kostrzewa RM. Lichen planus limited to the nails. *Arch Dermatol*. 1969;100:371.
8. Zaias N. The nail in lichen planus. *Arch Dermatol*. 1970;101:264-271.
9. Bhargava RK, Goyal RK. Solitary involvement of nails in lichen planus. *Int J Dermatol Venereol*. 1975;41:142.
10. Baran R, Dupré A, Christol B, Bonafe JL, Sayag J, Ferrere J. L'ongle grésé peladique. *Ann Dermatol Venereol*. 1978;105:387-392.
11. Peluso AM, Tosti A, Piraccini BM, Cameli N. Lichen planus limited to the nails in childhood: case report and literature review. *Pediatr Dermatol*. 1993;10:36-39.
12. Tosti A, Peluso AM, Fanti PA, Piraccini BM. Nail lichen planus: clinical and pathologic study of 24 patients. *J Am Acad Dermatol*. 1993;28:724-730.
13. Boyd AS, Neldner KH. Lichen planus. *J Am Acad Dermatol*. 1991;25:593-619.
14. Baran R, Tosti A. Nails. In: Freedberg IM, Eisen AZ, Wolff K, et al, eds. *Fitzpatrick's Dermatology in General Medicine*. 5th ed. New York, NY: McGraw-Hill; 1999:752-768.
15. Milligan A, Graham-Brown RAC. Lichen planus in children: a review of six cases. *Clin Exp Dermatol*. 1990;15:340-342.
16. Baran R, Dawber RPR. The nail in dermatological diseases. In: Baran R, Dawber RPR, eds. *Diseases of the Nails and their Management*. Oxford, England: Blackwell Scientific Publications; 1994:135-173.
17. Tosti A, Piraccini BM. Trachyonychia or twenty-nail dystrophy. *Curr Opin Dermatol*. 1996;3:83-86.
18. Del Rosso JK, Basuk PJ, Scher RK, Ricci AR. Dermatologic diseases of the nail unit. In: Scher RK, Daniel CR III, eds. *Nails: Therapy, Diagnosis, Surgery*. 2nd ed. Philadelphia, Pa: WB Saunders Co; 1997:172-200.
19. Tosti A, Bardazzi F, Piraccini BM, Fanti PA. Idiopathic trachyonychia (twenty nail dystrophy): a pathological study of 23 patients. *Br J Dermatol*. 1994;131:866-872.
20. Samman PD, Fenton DA. Miscellaneous acquired nail disorders. In: Samman PD, Fenton DA, eds. *Samman's The Nails in Disease*. 5th ed. Oxford, England: Butterworth-Heinemann Ltd; 1995:97-100.
21. Tosti A, Piraccini BM, Fanti PA, Bardazzi F, Di Landro A. Idiopathic atrophy of the nails: clinical and pathological study of 2 cases. *Dermatology*. 1995;190:116-118.
22. Sharma R, Maheshwari V. Childhood lichen planus: a report of fifty cases. *Pediatr Dermatol*. 1999;16:345-348.