

ORIGINAL ARTICLE

International consensus recommendations on the aesthetic usage of botulinum toxin type A (Speywood Unit) – part I: upper facial wrinkles

B Ascher,^{†,*} S Talarico,[‡] D Cassuto,[§] S Escobar,[¶] D Hexsel,^{**} P Jaén,^{††} GD Monheit,^{‡‡} B Rzany,^{§§} M Viel^{¶¶}

[†]Clinique de Chirurgie Esthétique Iéna, Paris, France

[‡]Universidade Federal de San Paulo, San Paulo, Brazil

[§]University of Catania, Milan, Italy

[¶]Universidad de Buenos Aires, Buenos Aires, Argentina

^{**}Pontificia Universidade Católica do Rio Grande do Sul, Porto Alegre, Brazil

^{††}Ramon y Cajal Public Hospital, Madrid, Spain

^{‡‡}Total Skin and Beauty Dermatology Center, Birmingham, AL, USA

^{§§}dEBM, Klinik für Dermatologie, Charité-Universitätsmedizin, Berlin, Germany

^{¶¶}London Centre for Aesthetic Surgery, London, UK

*Correspondence: B Ascher. E-mail: benjaminascher@wanadoo.fr

Abstract

Background Azzalure (Galderma SA) is a newly approved European botulinum neurotoxin type A (BoNT-A). It is derived from Dysport (Ipsen Pharma), which has a long history of usages in various applications. Azzalure and Dysport are collectively referred to as BoNT-A (Speywood Unit) and are different from other BoNT-A preparations.

Objective To provide consensus recommendations on the treatment of upper face wrinkles with BoNT-A (Speywood Unit).

Methods The members of the International Board on Botulinum toxin Azzalure (IBBA) convened to develop consensus on the treatment of upper facial wrinkles based on their own extensive experience.

Results The consensus recommendations address the general issues regarding treatment and provide specific guidelines on the anatomy, injection points, dose, injection technique and safety precautions concerning each common upper face indication. The recommended final concentration of BoNT-A (Speywood Unit) is 200 s.U./mL (10 s.U./0.05 mL) after reconstitution. For glabellar lines, the members recommend a total of five injection points with 10 s.U./point. For forehead wrinkles, the members recommend four to six injections into the frontalis with 5–10 s.U./point. For crow's feet, the members recommend three injections per side with 5–10 s.U./point at the lateral part of the orbicularis oculi. For lateral eyebrow lift, the members recommend one point at each eyebrow tail and an additional one in each side of the frontalis with 5–10 s.U./point.

Conclusion This guideline provides a framework for physicians who wish to perform safe and efficacious injection of BoNT-A (Speywood Unit).

Received: 17 November 2009; Accepted: 28 January 2010

Keywords

botulinum toxin type A, consensus, facial wrinkle, Speywood

Conflict of interest

B. Ascher and B. Rzany have served as advisor, speaker and investigator for Galderma, Ipsen and Merz Pharma., S. Talarico, D. Cassuto, S. Escobar, P. Jaén and M. Viel are consultants for Galderma. D. Hexsel has served as consultant, speaker or researcher for the companies which own toxins. GD. Monheit is a consultant for Galderma and Ipsen.

Introduction

Treatment with botulinum neurotoxin type A (BoNT-A) is a frequently performed non-invasive cosmetic procedure. When

injected into muscles, BoNT-A blocks the release of the neurotransmitter acetylcholine and, as a result, helps to smooth wrinkles and therefore may improve patient's quality of life.^{1,2}

Table 1 Comparisons among various commercial botulinum neurotoxin type A (BoNT-A) preparations approved for aesthetic usage

	Vistabel/Botox	BoNT-A (Speywood Unit)		
		Azzalure	Dysport (300 s.U)	Dysport (500 s.U)
Company	Allergan Inc.	Galderma SA	Medicis Pharmaceutical Co.	Ipsen Pharma
Biological activity	50 or 100 U/vial	125 s.U/vial	300 s.U/vial	500 s.U/vial
Approved for aesthetic usages	Yes	Yes (in Europe)	Yes (in US)	Yes (in 5 countries around the world)
Stabilisation	Vacuum dried	Lyophilised		

Several commercial preparations of BoNT-A products are available for aesthetic usage. Among them, Azzalure (Galderma SA, Lausanne, Switzerland)/Dysport (Ipsen Pharma, Boulogne-Billancourt, France) and Vistabel/Botox (Allergan Inc., Irvine, CA, USA) are the two most widely used products (Table 1). They are produced from different strains of bacteria, purified and stabilised using different methods and therefore have distinct chemical and biological properties.¹ As the bioassays employed for activity measurement are different for Azzalure/Dysport and Vistabel/Botox, the units of these BoNT-A products are not interchangeable.^{3,4} Azzalure and Dysport are quantified in Speywood Units (s.U), after the name of the company (Speywood Biopharm Ltd., Maidenhead, Berkshire, UK) who originally developed the product. They are hereafter collectively referred to as BoNT-A (Speywood Unit).

Dysport is available in two different quantities, containing 500 and 300 s.U respectively. Dysport (500 s.U) has a 20-year history of product consistency and safety in both therapeutic and aesthetic usages.⁵⁻⁸ Dysport (300 s.U) was approved in the U.S as abobotulinumtoxin A for aesthetic indication. Azzalure is derived from the same bulk as Dysport, albeit in a different quantity (125 s.U). It is specifically designed and approvals have been received recently for aesthetic usages in 15 European countries.

Treatment in the glabellar region is the only labelled aesthetic indication of BoNT-A products. Nevertheless, physicians routinely inject BoNT-A to treat wrinkles in other facial and neck areas.^{5,9-11} Although the procedure is generally effective and safe, a full understanding of both BoNT-A properties and facial anatomy is essential to ensure optimal treatment results. As there are only a few clinical studies and regional guidelines available on the off-label indications,¹²⁻¹⁸ international consensus recommendations would be helpful in providing a general guideline for effective and safe injection of BoNT-A (Speywood Unit).

Methods of consensus development

The International Board on Botulinum toxin Azzalure (IBBA) comprises nine dermatologists/plastic surgeons who have extensive experience in the aesthetic usages of BoNT-A (Speywood Unit). In addition, three board members (Ascher, Rzany and Monheit) were leading investigators of several large-scale clinical studies on the efficacy and safety of BoNT-A (Speywood Unit) in the treatment of glabellar lines and crow's feet. Board members convened to develop the following consensus recommendations on various

upper face indications, based on their own experience during clinical practice and based on the results of large clinical studies if they were available. A strong consensus was defined as approval from at least 90% of the board members (eight of nine members).

Consensus recommendations were developed to provide simple guidelines for safe injection. Specifically, treatment safety is ensured when the injector uses the recommended reconstitution volume, injection points, dose and the correct injection technique (Table 2). Highly risky injection points were not suggested; nor were indications requiring extensive experience. Strong consensus was achieved for all four upper face indications. It is important to note that the recommendations provided here refer to BoNT-A (Speywood Unit), which includes Azzalure and Dysport and cannot be applied to other formulations or preparations of BoNT-A.

Consensus recommendations

General preparation

Patient management. Patient education and counselling are integral parts of the BoNT-A treatment. It is essential for the patients to have a realistic expectation of the treatment outcome, as their expectations determine the level of satisfaction after treatment.¹⁹ During counselling, the physicians should first analyse the patient's requests and be attentive to the difference between objective and subjective perceptions. They should also analyse the facial anatomy, observing patients at rest and during movement, while paying attention for any pre-existing asymmetry. The physicians should then propose a coherent treatment plan based on the patient's request, facial anatomy and the status of skin ageing.

Next, the physicians should introduce BoNT-A, explaining its mode of action, long history of usage and good record of safety. The injection procedure needs to be explained to patients, as well as the estimated onset of action and duration of effect. The physicians should also explain potential adverse events and, if necessary, the treatment to correct those undesired outcomes. Patients should be clearly informed if they are about to receive injections for an off-label indication, and all patients should read and sign an informed consent form before treatment.

To assess the treatment outcome, it is recommended especially in new patients to schedule a follow-up appointment about 3-6 weeks after the initial injection. Patients and physicians should

Table 2 Consensus recommendations on the injection points, dose and technique for common upper face indications of botulinum neurotoxin type A (BoNT-A) (Speywood Unit)

Indication	Dose per injection point (s.U)	No. injection points	Total dose (s.U)	Injection site	Injection technique
Glabellar lines	10	5	50	0.5–1 cm from the upper orbital rim and internal to the mid-pupillary lines	Deep intramuscular and perpendicular injections to the last third of a 30G needle
Horizontal forehead lines	5–10	4–6	20–60	Under the hairline, V-shape in women and straight in men, if applicable	Superficial intramuscular and perpendicular injections to the middle third of an 30G needle
Crow's feet	5–10	3 per side, total 6 points	30–60	External part of the orbicularis oculi, 1–2 cm from the external orbital rim	Superficial injections with needle pointing away from the eyes (20–30° angle to the skin), to the first third of a 30G needle
Lateral eyebrow lift	5–10	2 per side, total 4 points	20–40	One point at each eyebrow tail, and the other at the external part of the frontalis	Superficial intramuscular and perpendicular injections to the middle third of a 30G needle

compare the before and after treatment photos and/or videos and estimate their level of satisfaction. If needed, patients can receive a touch-up treatment with small doses during the appointment.

Reconstitution. The volume of reconstitution can be adapted according to the quantity of product, physician's preference and patient's needs, following the recommendations of health authorities in different regions around the world. We recommend reconstituting the lyophilised powder of BoNT-A (Speywood Unit) in preservative-free 0.9% sodium chloride solution to obtain a final concentration of 200 s. U/mL (10 s. U/0.05 mL). This was the concentration used in the majority of international clinical studies for the treatment of glabellar lines with BoNT-A (Speywood Unit).^{20–25} The recommended volume for reconstituting Azzalure and Dysport (300 and 500 s. U) is summarised in Table 3. Reconstituting Azzalure and Dysport using the recommended volumes would result in the same concentration for all preparations of BoNT-A (Speywood Unit) and ensure treatment consistency.

Azzalure is designed for single-use and should be reconstituted just before injection. BoNT-A (Speywood Unit) should be stored in the refrigerator no longer than 4 h after reconstitution.^{26,27} For Dysport, it was reported that reconstituted vials can be stored at 4–8°C for up to 15 days without having microbiological contamination or causing significant decrease in treatment efficacy.²⁸

Syringe and needle for injection. A 1 mL insulin-type syringe bearing the graduations of 10 s. U and 0.01 mL was specially designed for reconstitution and injection of Azzalure. A 30G-13 mm needle is standard and is recommended for the injection of BoNT-A (Speywood Unit). The length of the needle is divided into three parts (the first, middle and last third) and the position of the needle is hereafter used as an indication of injection depth.

Glabellar lines

BoNT-A (Speywood Unit) is indicated for the treatment of moderate-to-severe vertical lines in glabella. The efficacy and safety of this treatment using BoNT-A (Speywood Unit) have been demonstrated in several large-scale, double-blind, randomised and placebo-controlled clinical studies in multiple centres around the world.^{20–25,29–31}

Anatomy. The eyebrow depressor muscles consist of the procerus, the corrugator, the depressor supercillii and the orbicularis oculi. The procerus covers the nasal bones in which it inserts. The corrugator supercillii is a narrow, strong muscle with deep medial insertions on the glabellar periosteum and another more superficial lateral insertion in the skin above the medial portion of the eyebrow. The orbicularis oculi muscle is a thin, broad muscle

Table 3 Recommended reconstitution volume for botulinum neurotoxin type A (BoNT-A) (Speywood Unit)

	Final volume (mL)	Final concentration	Injection volume for		
			10 s.U	5 s.U	2 s.U
Azzalure (125 s.U)	0.63*	200 s.U/mL (10 s.U/0.05 mL)	50 µL (0.05 mL)	25 µL (0.025 mL)	10 µL (0.01 mL)
Dysport (300 s.U)	1.5				
Dysport (500 s.U)	2.5				

*A specifically designed syringe adapted to the reconstitution volume is included with the product.

encircling the eye and adhering to the skin. The medial fibres of the orbicularis oculi and the frontalis are intertwined with the corrugator and may contribute to wrinkle formation in this region. Contracting the corrugator and depressor supercilii produces vertical lines between the eyebrows, while contracting the procerus induces a horizontal line.

Injection point, dose and technique. For the treatment of glabellar lines, a five-point injection is recommended, with one point in the procerus and two points in each corrugator (Fig. 1). All points should be 0.5–1 cm from the upper orbital rims and internal to the mid-pupillary lines. The injection sites are the same as those used in European studies.^{22,29} Injection should be perpendicular, intramuscular and deep, to the last third of a 30G needle.

The recommended total dose is 50 s. U, equally distributed among the five injection points, with 10 s.U (0.05 mL)/point. The treatment efficacy and duration of 50 s.U were similar to those of 75 s.U, while higher patient satisfaction was reported in the 50 s.U group.^{29,30} The recommended dose range for this indication is 30–70 s.U. The final dosage for each individual depends on their muscle structure, the wrinkle severity and patient's preference of a

more natural or a more static look. Dose should also be adjusted based on muscle mass, as bigger muscle requires a higher dose to achieve a similar effect.³¹

Safety concerns. Headache and injection site reactions are the most frequently reported adverse events for this indication.^{26,27} Eyelid ptosis, caused by involuntary involvement of the levator palpebrae, can be prevented by adopting the recommended injection points and volume. The incidence of eyelid ptosis is usually considered technique-dependent and was low in clinical studies even after repeated treatments with BoNT-A (Speywood Unit).^{20–25,29–31} If ptosis occurs, it should be noted that the symptom is temporary and usually subsides within a few weeks, with no additional treatment required.

Horizontal forehead lines

Although this indication belongs to the off-label use of BoNT-A, it is commonly practised, either alone or combined with the treatment of the glabellar region. Injection of BoNT-A (Speywood Unit) in the forehead is safe and effective in weakening horizontal wrinkles.^{5,32–34}

Anatomy. The frontalis is a large, thin muscle closely attached to the skin. Its medial fibres are joined at the glabellar region, where they intersect with the procerus. Its central and lateral fibres blend in with the corrugator supercilii and the inner part of the orbicularis oculi. Contraction of the frontalis raises the eyebrows and the upper eyelid, causing the formation of horizontal forehead rhytides.

Injection point, dose and technique. For the treatment of horizontal forehead lines, a total of four to six points are recommended in the forehead below the hairline (Fig. 2). The points should form a slightly curved V-shape in women, and straight in men if applicable. For less experienced injectors, the points should be sufficiently high on the forehead (about 4–5 cm from the orbital rim) to avoid side effects such as brow ptosis. The lateral points should be on the external orbital rim lines.

There is currently no dose-finding study performed on this indication. The board members recommend a total dose range of 20–60 s.U, with 5–10 s.U/point. As the frontalis is a low-dose reactive muscle, it is recommended to first start with a small dose to avoid a 'frozen' look. Injection should be superficial, intramuscular and perpendicular to the skin, to the middle third of a 30G needle.

Safety concern. To avoid brow ptosis, injection points should be in the upper two-thirds of the forehead, sufficiently high above the brow depressor. The minimal dose should be used first to ensure treatment safety. If brow ptosis occurs, it should be noted that the symptom is temporary and usually does not require additional treatment.

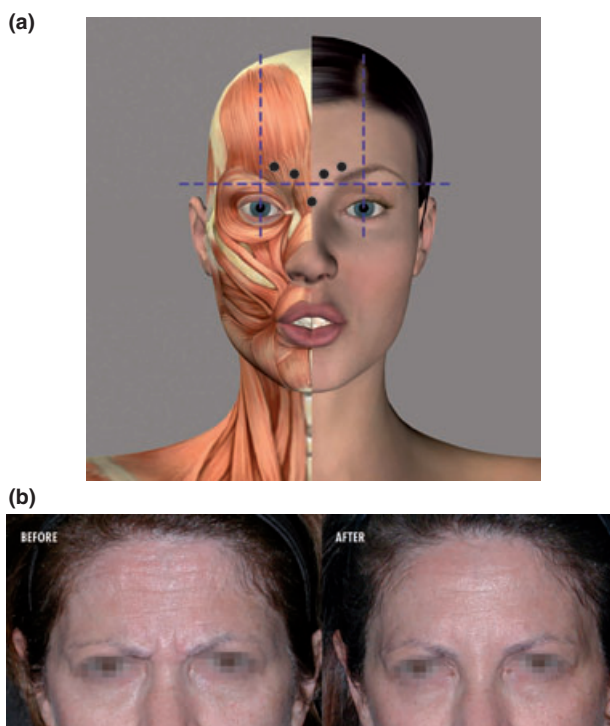


Figure 1 Treatment of glabellar lines (a) Recommended injection points, the mid-pupillary lines and the upper orbital rim line are illustrated (graph modified from de Maio and Rzyany⁹). (b) Photos of a patient at maximum frown before and 30 days after the treatment with 50 s.U BoNT-A (Speywood Unit). Courtesy of B. Ascher.

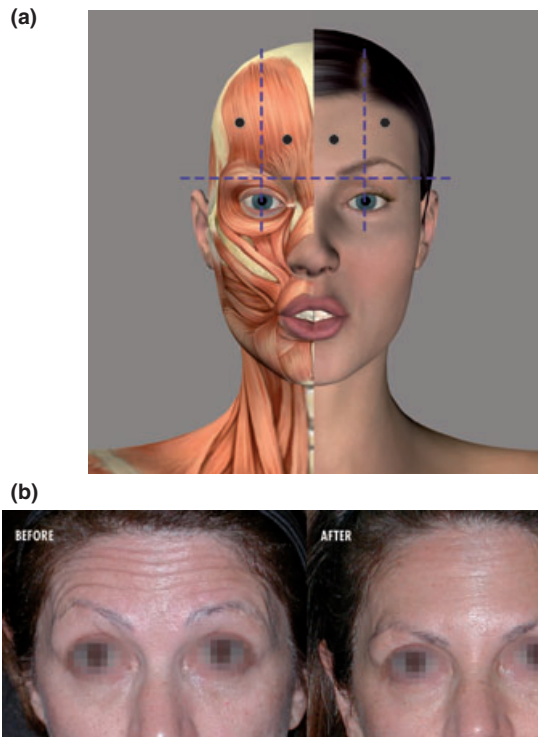


Figure 2 Treatment of horizontal forehead lines. (a) Recommended injection points, the mid-pupillary lines and the upper orbital rim line are illustrated (graph modified from de Maio and Rzany⁹). (b) Photos of a patient at maximum contraction before and 30 days after the treatment with 40 s.U BoNT-A (Speywood Unit). *Courtesy of B. Ascher.*

If the external injection points are too close to the centre, movement of the lateral frontalis can lead to wrinkle formation above the lateral part of the eyebrows. This sign can be avoided by carefully assessing the position of the eyebrows before treatment, and placing the lateral points on the external orbital rim lines.

Crow's feet

Crow's feet are dynamic lateral orbital wrinkles that appear when smiling, and static wrinkles in this region caused by photoageing. This is a common off-label indication and usually yields good treatment results.^{5,13,33,34} Treatment of crow's feet with BoNT-A (Speywood Unit) is both effective and safe, as demonstrated in a multi-centre, double-blind, randomised and placebo-controlled study.¹³ Although effective in reducing hyperkinetic lines, BoNT-A treatment is not suitable for treating the static wrinkles caused by photoageing or sleeping habits.

Anatomy. The orbicularis oculi is usually divided into three portions: the lacrimal portion at the medial side of the orbit, which is the smallest and the innermost portion; the palpebral portion that raises the eyelids and controls the involuntary action of blinking; and the orbital portion or pars orbicularis, which

surrounds the orbit with concentric fibres, blends into the frontalis and extends to the masseter. All three portions of the orbicularis oculi need to function correctly to control the voluntary closing of the eyelids.

Injection point, dose and technique. For the treatment of crow's feet, injection with three points per side (six points in total) in the canthal region is recommended (Fig. 3). All points should be at the external part of the orbicularis oculi and about 1–2 cm from the external orbital rim. The recommended injection points are the same as those used in the clinical study.¹³ A total dose of 30–60 s.U is recommended, with 5–10 s.U/point and 15–30 s.U/side. Treatment of crow's feet with 15, 30 or 45 s.U BoNT-A (Speywood Unit) per side resulted in a slightly dose-dependent but largely similar response rate.¹³ The minimal injection dose should be adopted to avoid a 'frozen look' when smiling and to ensure treatment safety. Injection should be lateral (20–30° angle to the skin) and superficial to the first third of the needle.

Crow's feet can be combined and treated together with lower eyelid wrinkles if they are present. In this case, the same injection points should be used with a slightly lower dose per point.

Safety concerns. Patient selection is crucial for this indication and the injector should avoid patients with dry eyes,

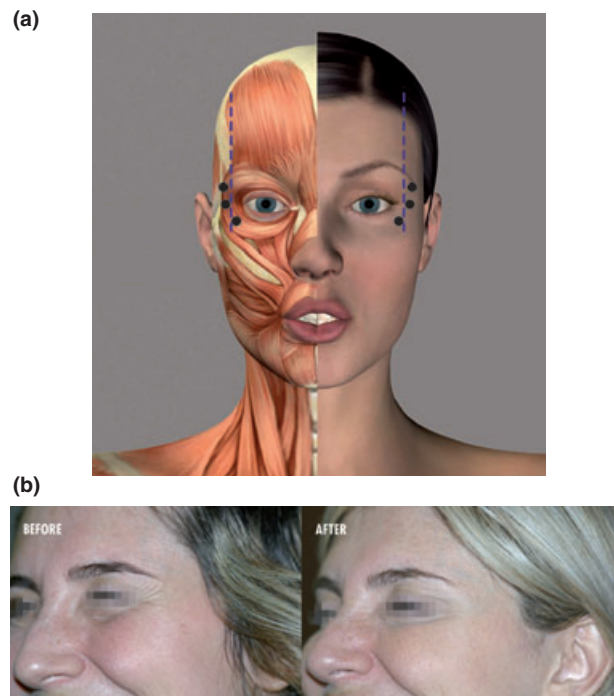


Figure 3 Treatment of crow's feet (a) Recommended injection points and the external orbital rim lines are illustrated (graph modified from de Maio and Rzany⁹). (b) Photos of a patient when smiling before and 30 days after the treatment with 30 s.U BoNT-A (Speywood Unit) per side. *Courtesy of D. Cassuto.*

prominent eye bags, scleral show or morning eyelid oedema. In addition, patients need to have a positive snap test and preferably good skin elasticity.

It is recommended that the injector positions himself or herself opposite to the treatment side, so that the needle points away from the patient's eyes. The injector should use optimal lighting and stretch the skin slightly to avoid injecting into blood vessels. To avoid ecchymosis, injection should be very superficial and applying ice before and after injection may also be helpful. Deep injection or injection into the inferior region of the zygomaticus major should be avoided, as it may lead to unwanted effects such as drooping mouth corners.

The most frequently reported treatment-related adverse event was mild periorbital haematoma. One 1 subject reported eyelid ptosis among a total of 164 receiving BoNT-A (Speywood Unit) of various doses.¹³ Eyelid ptosis can be avoided by injecting superficially and using the minimal injection dose and volume.

Lateral eyebrow lift

Eyebrows are usually positioned at the supraorbital rim or just above it. When the lateral part of the eyebrow drops, a tired or sad look appears. BoNT-A treatment is the most commonly adopted procedure to correct this sign. The injection procedure is effective, safe and easy to perform compared to surgical approaches. This is an off-label indication usually performed in women only and in combination with other upper face treatments. A full understanding of the muscles involved in determining brow position is essential.

Anatomy. The frontalis serves as an elevator of the eyebrows to maintain their normal position and to lift them to produce an expression of surprise. The corrugator, the procerus and the orbicularis oculi intervene with the frontalis and act as depressors of the brow position. Contraction of the corrugator and the procerus pull the internal and the medial part of the eyebrow downward; whereas contraction of the pars orbicularis pulls the eyebrow tail downward.

Injection point, dose and technique. A four-point injection with two points per side is recommended (Fig. 4). One injection point should be placed at each eyebrow tail into the pars orbicularis. Once injected, BoNT-A blocks the depressor while the frontalis functions normally to elevate the lateral part of the eyebrow. Two additional injection points should be placed at the external part of the frontalis, slightly more internal than the orbicularis points. Injection in this part of the frontalis can further drop the medial brow, reshape the entire eyebrow and accentuate the lateral arch.

The recommended dose is 5–10 s.U./point and the total dose range is 20–40 s.U. The final dose should be adjusted based on expected treatment outcome, muscle mass and relative strength of the orbicularis oculi and the frontalis. Injection should be superfi-

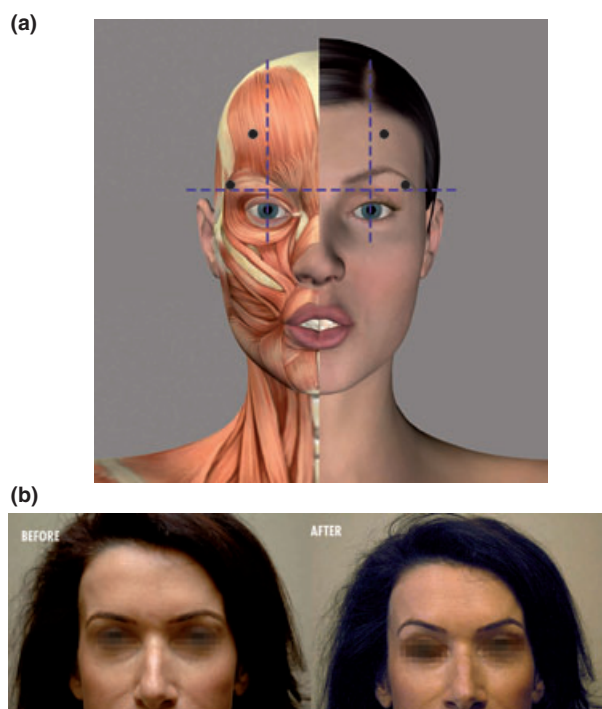


Figure 4 Lateral eyebrow lift. (a) Recommended injection points, the mid-pupillary lines and the upper orbital rim line are illustrated (graph modified from de Maio and Rzany⁹). (b) Photos of a patient at rest before and 7 days after the eyebrow lift treatment with 20 s.U BoNT-A (Speywood Unit). *Courtesy of M. Viel.*

cial, intramuscular and perpendicular to the skin, to the middle third of the needle.

Safety concerns . This treatment is usually effective and safe. Eyelid and brow ptosis occur only rarely when the injection volume is too large or when the injection sites are too close to the orbital rim. However, these adverse events can be prevented if the recommended injection dose and techniques are adopted.

Summary

By developing the consensus recommendations, the panel members, all of whom have extensive experience with BoNT-A (Speywood Unit), provide a general guideline for the safe and effective injection with this specific BoNT-A preparation. The consensus recommendations address issues regarding the treatment with BoNT-A (Speywood Unit) in general and each commonly practised indication in the upper face. The general issues include product reconstitution, choice of syringe and needle, as well as patient management and selection. For each upper face indication, anatomy is briefly reviewed and the recommended injection points, dose and injection technique are provided. The consensus recommendations help to ensure the maximal treatment safety

and effectiveness, and serve as a starting point for further adaptations among individuals in clinical practice.

Acknowledgement

The authors thank Dr Y. May Ma for editorial assistance.

References

- Huang W, Foster JA, Rogachefsky AS. Pharmacology of botulinum toxin. *J Am Acad Dermatol* 2000; **43**: 249–259.
- Sadick NS. The impact of cosmetic interventions on quality of life. *Dermatol Online J* 2008; **14**: 2.
- Pickett AM, Hambleton P. Dose standardisation of botulinum toxin. *Lancet* 1994; **344**: 474–475.
- Karsai S, Raulin C. Current evidence on the unit equivalence of different botulinum neurotoxin A formulations and recommendations for clinical practice in dermatology. *Dermatol Surg* 2008; **34**: 1–8.
- Rzany B, Dill-Müller D, Grablowitz D, Heckmann M, Carid D. Repeated botulinum toxin A injections for the treatment of lines in the upper face: A retrospective study of 4103 treatments in 945 patients. *Dermatol Surg* 2007; **33**: S18–S25.
- Markey AC. Dysport. *Dermatol Clin* 2004; **22**: 213–219.
- Van den Bergh P, Francart J, Mourin S, Kollmann P, Laterre EC. Five-year experience in the treatment of focal movement disorders with low-dose Dysport botulinum toxin. *Muscle Nerve* 1995; **18**: 720–729.
- Jitpimolmard S, Tiamkao S, Laopaiboon M. Long term results of botulinum toxin type A (Dysport) in the treatment of hemifacial spasm: a report of 175 cases. *J Neurol Neurosurg Psychiatry* 1998; **64**: 751–757.
- de Maio M, Rzany B. *Botulinum Toxin in Aesthetic Medicine*. Springer, Heidelberg, 2007.
- Ascher B, Landau M, Rossi B. Injection treatments in cosmetic surgery. Informa Healthcare, London. Editor 2008
- Carruthers A, Carruthers J. A single-center, dose-comparison, pilot study of botulinum neurotoxin A in female patients with upper facial rhytides: safety and efficacy. *J Am Acad Dermatol* 2009; **60**: 972–979.
- Lowe NJ, Ascher B, Heckmann M, Kumar C, Fraczek S, Eadie N. Double-blind, randomized, placebo-controlled, dose-response study of the safety and efficacy of botulinum toxin type A in subjects with crow's feet. *Dermatol Surg* 2005; **31**: 257–262.
- Ascher B, Rzany BJ, Grover R. Efficacy and safety of botulinum toxin type A in the treatment of lateral crow's feet: double-blind, placebo-controlled, dose-ranging study. *Dermatol Surg* 2009; **35**: 1478–1486.
- Flynn TC, Carruthers JA, Carruthers JA, Clark RE II. Botulinum A toxin (BOTOX) in the lower eyelid: dose-finding study. *Dermatol Surg* 2003; **29**: 943–950.
- Rzany B, Fratila A, Heckmann M. Expertentrfen zur Anwendung von Botulinumtoxin A in der Ästhetischen Dermatologie. *Kosmetische Medizin* 2005; **3**: 1–8.
- Sommer B, Bergfeld D, Sattler G. Consensus recommendations on the use of botulinum toxin type A in aesthetic medicine. *J Dtsch Dermatol Ges* 2007; **5**(Suppl. 1): S1–S29.
- Carruthers J, Fagien S, Matarasso SL. Consensus recommendations on the use of botulinum toxin type A in facial aesthetics. *Plast Reconstr Surg* 2004; **114**(Suppl. 1): S1–S22.
- Carruthers J, Glogau RG, Blitzer A. Advances in facial rejuvenation: botulinum toxin type A, hyaluronic acid dermal fillers, and combination therapies – consensus recommendations. *Plast Reconstr Surg* 2008; **121**: S5–S30.
- Lewis CM, Lavell S, Simpson MF. Patient selection and patient satisfaction. *Clin Plast Surg* 1983; **10**: 321–332.
- Ascher B, Zakine B, Kestemont P et al. Botulinum toxin A in the treatment of glabellar lines: scheduling the next injection. *Aesthet Surg J* 2005; **25**: 365–375.
- Rzany B, Ascher B, Fratila A, Monheit G, Talarico S, Sterry W. Efficacy and safety of 3- and 5-injection patterns (30 and 50 U) of botulinum toxin A (Dysport) for the treatment of wrinkles in the glabella and the central forehead region. *Arch Dermatol* 2006; **142**: 320–326.
- Moy R, Maas C, Monheit G, Huber MB. Long-term safety and efficacy of a new botulinum toxin type A in treating glabellar lines. *Arch Facial Plast Surg* 2009; **11**: 77–83.
- Rubin MG, Dover J, Glogau RG, Goldberg DJ, Goldman MP, Schlessinger J. The efficacy and safety of a new U.S. Botulinum toxin type A in the re-treatment of glabellar lines following open-label treatment. *J Drugs Dermatol* 2009; **8**: 439–444.
- Brandt F, Swanson N, Baumann L, Huber B. Randomized, placebo-controlled study of a new botulinum toxin type A for treatment of glabellar lines: efficacy and safety. *Dermatol Surg* 2009; **35**: 1893–1901.
- Monheit GD, Cohen JL. Long-term safety of repeated administrations of a new formulation of botulinum toxin type A in the treatment of glabellar lines: interim analysis from an open-label extension study. *J Am Acad Dermatol* 2009; **61**: 421–425.
- Galderma SA. Azzalure, Summary of Product Characteristic (SmPC). [WWW document] 2008. URL <http://emc.medicines.org.uk/medicine/21985> (last accessed: 4 March 2010).
- Ipsen Ltd. Dysport, Summary of Product Characteristics (SmPC). [WWW document] 2007 URL <http://emc.medicines.org.uk/medicine/870/SPC/Dysport/> (last accessed: 4 March 2010).
- Hexsel D, Rutowitsch MS, de Castro LC, do Prado DZ, Lima MM. Blind multicenter study of the efficacy and safety of injections of a commercial preparation of Botulinum toxin Type A reconstituted up to 15 days before injection. *Dermatol Surg* 2009; **35**: 933–939.
- Ascher B, Zakine B, Kestemont P, Baspeyras M, Bougara A, Santini J. A multicenter, randomized, double-blind, placebo-controlled study of efficacy and safety of 3 doses of botulinum toxin A in the treatment of glabellar lines. *J Am Acad Dermatol* 2004; **51**: 223–233.
- Monheit G, Carruthers A, Brandt F, Rand R. A randomized, double-blind, placebo-controlled study of botulinum toxin type A for the treatment of glabellar lines: determination of optimal dose. *Dermatol Surg* 2007; **33**: S51–S59.
- Kane MA, Rohrich RJ, Narins RS, Monheit GD, Huber MB. Evaluation of variable-dose treatment with a new U.S. botulinum toxin type A (Dysport) for correction of moderate to severe glabellar lines: results from a phase 3, randomized, double-blind, placebo-controlled study. *Plast Reconstr Surg* 2009; **124**: 1619–1629.
- Karsai S, Adrian R, Hammes S, Thimm J, Raulin C. A randomized double-blind study of the effect of Botox and Dysport/Reloxin on forehead wrinkles and electromyographic activity. *Arch Dermatol* 2007; **143**: 1447–1449.
- Farahvash MR, Arad S. Clostridium botulinum type A toxin for the treatment of upper face animation lines: an Iranian experience. *J Cosmet Dermatol* 2007; **6**: 152–158.
- Dewandre L, Voloshchenko I, Trembach A. Etude comparative pilote de l'efficacité et de la durée d'activité de Dysport vs Botox dans les indications esthétiques classiques (front, glabella, patte d'oie). *J Méd Esth et Chir Derm* 2003; **118**: 101–107.